

Case Series

Cloaked bones in Mucopolipidosis II - A periosteal reaction in newborns

Sana Ashraf Khan¹, Sunita Kale¹, Hemangini Uday Thakkar¹, Zillani Alam¹

¹Department of Radiology, Seth Gordhandas Sunderdas Medical College and King Edward Memorial Hospital, Mumbai, Maharashtra, India.



*Corresponding author:

Sana Ashraf Khan,
Department of Radiology, Seth
Gordhandas Sunderdas Medical
College and King Edward
Memorial Hospital, Mumbai,
Maharashtra, India.

sana18597@gmail.com

Received: 05 September 2023

Accepted: 16 May 2024

Published: 26 June 2024

DOI

10.25259/IJMSR_46_2023

Quick Response Code:



ABSTRACT

On routine, antenatal ultrasound evaluation of a women at 35 weeks gestation showed a fetus (Case 1) with shortening of all the long bones (<5th percentile) with bowing and fuzzy margins. The baby was delivered full term. On physical examination, the baby had a fragile skull, narrow thorax, and short angulated limbs. Postnatal infantogram showed short long bones, periosteal cloaking, fractures, and bell shaped thorax. Another fetus (Case 2) with antenatal ultrasound done elsewhere was suggestive of short and bowed femur. At birth, the baby had angulated limbs. The infantogram shows the periosteal cloaking (thick periosteal reaction) and short long bones similar to the above-mentioned case. Both babies were positive for the I-cell screening test for Mucopolipidosis II. Case 1 was confirmed for the same with whole exome sequencing.

Keywords: Periosteal cloaking, Bowing, Angulated limbs, Bell-shaped thorax

INTRODUCTION

Mucopolipidosis II (also known as I-cell disease) is a genetically inherited autosomal recessive lysosomal storage disorder occurring due to a deficiency of lysosomal enzyme N-acetylglucosaminyl-phospho-transferase.^[1] The empty lysosomes accumulate in the fibroblasts of the bones; hence, skeletal changes are seen. The classic radiographic feature of “periosteal cloaking” is seen in Mucopolipidosis-II.

CASE SERIES

Case 1

On routine, antenatal ultrasound evaluation of a women at 35 weeks gestation showed a fetus with shortening of all the long bones (<5th percentile) with bowing and fuzzy margins.

1. Femur length: Abdominal circumference – 0.13 (i.e., <0.16) [Figure 1a]
2. Thoracic circumference: Abdominal circumference – 0.75 (should be <0.6 for lethality)
3. Thoracic circumference – <5th percentile [Figure 1b].

The above two values (1 and 3) indicate lethality.

The baby was delivered full term. On physical examination, the baby had a fragile skull, narrow thorax, and short angulated limbs.

This is an open-access article distributed under the terms of the Creative Commons Attribution-Non Commercial-Share Alike 4.0 License, which allows others to remix, transform, and build upon the work non-commercially, as long as the author is credited and the new creations are licensed under the identical terms.

©2024 Published by Scientific Scholar on behalf of Indian Journal of Musculoskeletal Radiology

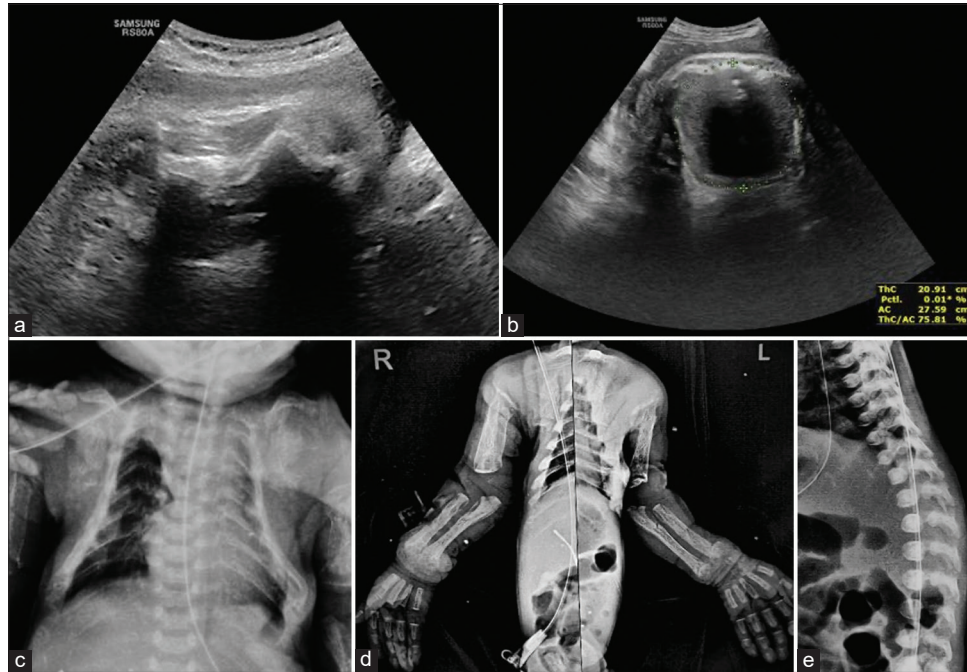


Figure 1: Images of Case 1. (a) Antenatal ultrasonogram of fetal femur shows a short, angulated femur with fuzzy margins. However, there is a good posterior acoustic shadowing suggesting normal bone density (in contrast to decreased bone density in Osteogenesis imperfecta). Femur length was <5th percentile for the gestational age. (b) Antenatal ultrasonogram at the level of thorax shows the thoracic circumference <5th percentile. (c) Postnatal radiograph of chest shows narrow (Bell-shaped) thorax with thin osteopenic ribs and hypoplastic scapulae. (d) Anteroposterior radiograph of both upper limbs shows short humeri, periosteal cloaking – severe periosteal reaction along all the long bones, fractures in the left ulna and left humerus, distal metaphyseal cupping, and splaying in both the radius and ulna. (e) Lateral radiograph of spine shows convex anterior margin of vertebrae (ovoid vertebrae).

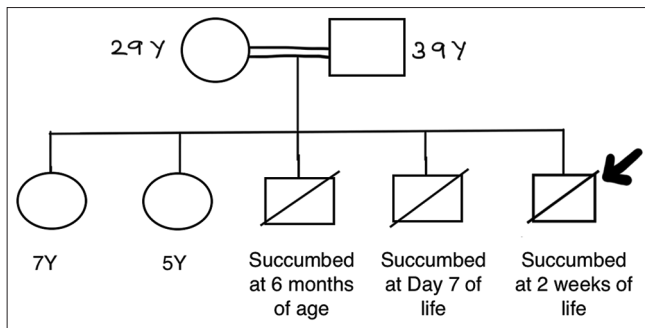


Figure 2: Pedigree chart for Case 1, Bold arrow indicates the child in Case 1.

Postnatal radiographs show

1. Narrow (Bell-shaped) thorax, thin osteopenic ribs, and hypoplastic scapulae [Figure 1c]
2. Short humeri, periosteal cloaking – severe periosteal reaction along all the long bones, fractures in the left ulna and left humerus, and distal metaphyseal cupping and playing in both the radius and ulna [Figure 1d]

3. Convex anterior margin of vertebrae (Ovoid vertebrae) [Figure 1e].

The baby was positive for I-cell screening test which showed decreased activity of the lysosomal enzyme. The absence of this enzyme was, further, confirmed with whole exome sequencing. Due to narrow chest circumference, the baby developed respiratory infection and succumbed after 2 weeks due to its complications. History of death in elder sibling was due to respiratory distress at 7th day of life, which is suggestive of genetic etiology [Figure 2].

Case 2

Another infant presented with short angulated limbs with antenatal ultrasound done elsewhere which was suggestive of short and bowed femur. The infantogram [Figure 3] shows the periosteal cloaking (thick periosteal reaction) and short long bones similar to above-mentioned case. This baby as well was positive for I-cell screening test for Mucopolipidosis II. Later, the baby developed respiratory infection and was under intensive care unit. Clinical images of both the cases have been shown in Figure 4.

DISCUSSION

Mucopolidosis II (also known as I-cell disease) is a genetically inherited autosomal recessive lysosomal storage disorder occurring due to a deficiency of lysosomal enzyme N-acetylglucosaminyl-phospho-transferase.^[1] The empty lysosomes accumulate in the fibroblasts of the bones; hence, skeletal changes are seen.

These patients can present at birth or within 6–10 months after birth. Clinical features include coarse facies, thick skin, joint contractures, or limb deformity. The most common cause of death is usually due to cardiorespiratory compromise.^[2]

Antenatal detection of this condition plays an important role in prognosis of the child. The assessment done with fetal ultrasound includes length of limbs (reduced femur length), abnormal shape (bowing, fractures, etc.), and reduced echogenicity.^[3] Chest circumference might be reduced. The section of head circumference shows reduced ossification of skull bones with hyper-visualization of intracranial structures. Definite diagnosis, however, depends on genetic workup in fetuses of skeletal dysplasia; however, one of the most important roles played by ultrasound is the determination of neonatal or infantile lethality.^[4] The cause of lethality in most skeletal

dysplasias is small chest circumference and resultant pulmonary hypoplasia. However, not all skeletal dysplasias associated with small thoracic circumferences are associated with immediate lethality. When associated abnormalities in other organ systems are detected, it increases morbidity and mortality.

The ultrasound criteria for lethality is:

1. Chest-to-abdominal circumference ratio of <0.6
2. Femur length-to-abdominal circumference ratios of <0.16 .^[5]

The early radiographic features seen in Mucopolidosis II^[6] are increased vertebral body height (80%, nonspecific), talocalcaneal stippling (86%), periosteal cloaking (74%), and vertebral body rounding (50%). Other findings included sacrococcygeal sclerosis (54%) and vertebral body sclerosis (13%). Rickets and hyperparathyroidism-like (pseudo-hyperparathyroidism) changes were also found in 33% of cases. These changes started in the newborn period. There is conversion from these early infantile radiographic features to dysostosis multiplex changes in 41% of cases.

The differential diagnosis for cases with shortened fetal long bones on antenatal ultrasound is a large number of skeletal dysplasias; hence, definitive diagnosis on antenatal ultrasound could not be given; however, the lethality of the dysplasia can be predicted.

However, the differentials for babies born with osteopenic fractures and shortened limbs include-

1. Congenital rickets/neonatal hyperparathyroidism
2. Hypophosphatasia
3. Osteogenesis imperfecta
4. Metabolic disease of preterm
5. Mucopolidosis II/I cell disease.

The biochemical parameters for both the cases were within normal limits ([Table 1] for Case 1). Hence, the possibility of congenital rickets and neonatal hyperparathyroidism was ruled out. Both the babies were born at term; hence, the possibility of metabolic disease of newborn was ruled out. Based on the [Table 2], radiographic diagnosis of Mucopolidosis II was made which was later confirmed with genetic workup. Prognosis of most affected children is that they do not survive past early childhood.^[7] There are currently no approved therapies to reverse the effects

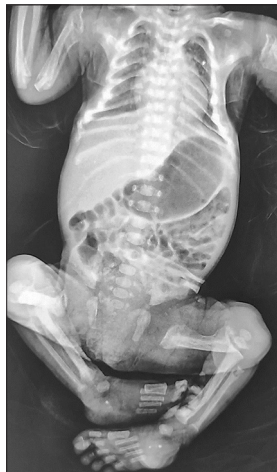

Figure 3: Image of Case 2. Postnatal infantogram shows periosteal cloaking (thick periosteal reaction) and short long bones in all limbs.

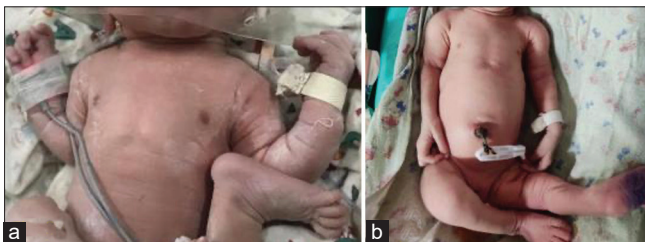


Figure 4: Clinical image of Case 1 and Case 2. (a) Case 1: Angulated left forearm and hyper-flexed left leg. (b) Case 2: Angulated left leg.

Table 1: Biochemical parameters of mother and baby for Case 1.

	Baby		Mother	
Calcium	8.4	within normal limits	9.1	within normal limits
Phosphorus	6	within normal limits	6.5	within normal limits
Alkaline phosphatase	1100	Raised	120	within normal limits

Table 2: List of differential diagnosis.

	Osteogenesis imperfecta	Hypophosphatasia	Mucopolipidosis II
Long bones	Osteopenia Fractures Callus formation Metaphyseal widening -	Osteopenia Fractures - Metaphyseal lucencies or tongues Diaphyseal spurs and hypoplastic fibulae	Osteopenia Fractures - Metaphyseal fragmentation Periosteal cloaking and cortical erosions
Chest	Short thin ribs	Beaded ribs	Almost invisible or hypoplastic scapulae
Skull	Wormian bones	Deficient ossification with wide sutures	Metopic and coronal synostosis
Spine	-	Absent pedicle	Ovoid vertebral bodies Intervertebral disc calcifications
Pelvis	-	-	Flared iliac wings with horizontal acetabular roofs

of Mucopolipidosis II. Current approach is managing specific symptoms through targeted therapies.^[8]

CONCLUSION

Lethal skeletal dysplasias usually present in the first/early second trimester. We tend to report non-lethal skeletal dysplasia in 3rd trimester; however, these cases teach us not to overlook the possibility of lethality even in 3rd trimester.

Mucopolipidosis-II should be included as a rare differential for osteopenia with bone-within-bone appearance in newborns after ruling out other relatively common ones such as osteogenesis imperfecta, congenital rickets, and hypophosphatasia.

Ethical approval

The Institutional Review Board approval is not required.

Declaration of patient consent

The authors certify that they have obtained all appropriate patient consent.

Financial support and sponsorship

Nil.

Conflicts of interest

There are no conflicts of interest.

Use of artificial intelligence (AI)-assisted technology for manuscript preparation

The authors confirm that there was no use of artificial intelligence (AI)-assisted technology for assisting in the

writing or editing of the manuscript and no images were manipulated using AI.

REFERENCES

1. Kudo M, Brem MS, Canfield WM. Mucopolipidosis II (I-cell disease) and mucopolipidosis IIIA (classical pseudo-hurler polydystrophy) are caused by mutations in the GlcNAc-phosphotransferase α/β -subunits precursor gene. *Am J Hum Genet* 2006;78:451.
2. Chen H. Mucopolipidosis 2. In: Atlas of genetic diagnosis and counseling. Germany: Springer; 2016. p. 1-10.
3. The fetal medicine foundation. Available from: <https://fetalmedicine.org/education/fetal-abnormalities/skeleton/skeletal-dysplasia#> [Last accessed on 2023 Aug 25].
4. Yoshimura S, Masuzaki H, Gotoh H, Fukuda H, Ishimaru T. Ultrasonographic prediction of lethal pulmonary hypoplasia: Comparison of eight different ultrasonographic parameters. *Am J Obstet Gynecol* 1996;175:477-83.
5. Rahemtullah A, McGillivray B, Wilson RD. Suspected skeletal dysplasias: femur length to abdominal circumference ratio can be used in ultrasonographic prediction of fetal outcome. *Am J Obstet Gynecol* 1997; 177:864-9.
6. Lai LM, Lachman RS. Early characteristic radiographic changes in mucopolipidosis II. *Pediatr Radiol* 2016;46:1713-20.
7. Cathey SS, Leroy JG, Wood T, Eaves K, Simensen RJ, Kudo M, *et al.* Phenotype and genotype in mucopolipidoses II and III alpha/beta: A study of 61 probands. *J Med Genet* 2010;47: 38-48.
8. Mucopolipidosis II (ML II) - Boston children's hospital. Available from: <https://www.childrenshospital.org/conditions/mucopolipidosis-ii#> [Last accessed on 2023 Aug 25].

How to cite this article: Khan SA, Kale S, Thakkar HU, Alam Z. Cloaked bones in Mucopolipidosis II - A periosteal reaction in newborns. *Indian J Musculoskelet Radiol.* 2024;6:24-7. doi: 10.25259/IJMSR_46_2023