

Case Report

A Case of an Extrasosseous Pretibial Ganglion Cyst

Catrin Wigley¹, Guy Morris¹, Scott Evans¹, Rajesh Botchu²

¹Departments of Orthopedic Oncology, ²Department of Musculoskeletal Radiology, Royal Orthopedic Hospital, Birmingham, West Midlands, England.



*Corresponding author:

Rajesh Botchu,
Department of Musculoskeletal
Radiology, Royal Orthopedic
Hospital, Birmingham,
England.

drbrajesh@yahoo.com

Received : 01 October 19
Accepted : 08 October 19
Published : 30 December 19

DOI
10.25259/IJMSR_12_2019

Quick Response Code:



ABSTRACT

Pretibial lesion can have a plethora of differential diagnosis. We report a case of extrasosseous pretibial ganglion cyst which was referred to our orthopedic oncology service and described the imaging features.

Keywords: Pretibial, Ganglion, Cyst

INTRODUCTION

Pretibial ganglion cysts are relatively uncommon. These can mimic a tumor. We report a case of extrasosseous pretibial ganglion cyst and discuss Magnetic Resonance Imaging (MRI) features, etiology, and differential diagnosis.

CASE REPORT

A 49-year-old man presented with an anterior swelling on his right shin that had appeared over the past 6 months. There was no associated pain, but the lesion did vary in size. The patient was otherwise well and had no history of antecedent trauma or surgery. On examination, the lesion measured 7 cm by 5 cm, was fluctuant and had no signs of local lymphadenopathy. Lateral and anteroposterior (AP) radiographs showed no calcification or osseous abnormalities [Figure 1]. The pretibial subcutaneous lesion was of low signal on T1 and high on Short tau inversion recovery (STIR) sequences [Figure 2]. There was no communication between the lesion and the knee joint. Normal marrow signal was noted of the adjacent tibia, and there was no periosteal reaction. A differential diagnosis of myxoma and ganglion cyst was considered. A tru-cut biopsy was performed, and the specimen was evaluated histologically. The biopsy revealed the material to consist almost entirely of a mucoid acellular substance with a small fibrous connective tissue fragment at one side and no synovial lining. Based on clinical history, physical examination, radiology, and histological reports, a diagnosis of extrasosseous pretibial ganglion cyst was made.

DISCUSSION

Ganglion cysts are pseudocysts containing jelly-like fluid and lined by fattened cells. These usually arise from the joint or tendon sheath following extension of synovial fluid in to the adjacent soft tissues. Ganglion cysts in the pretibial region are extremely rare with few cases described in the literature. Of those reported, majority have been attributed as a rare complication of anterior cruciate ligament surgery.^[1-5] Maeseener *et al.* had demonstrated communication between

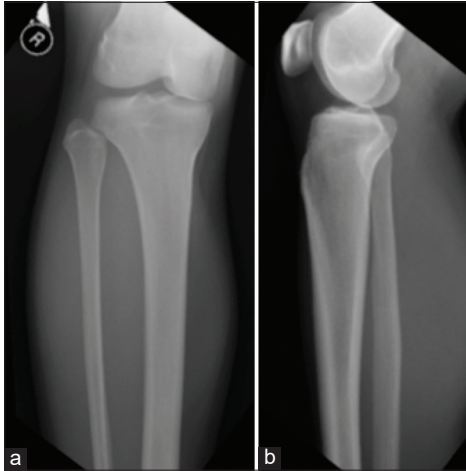

Figure 1: AP and lateral radiograph of knee does not show any calcification in the pretibial region.

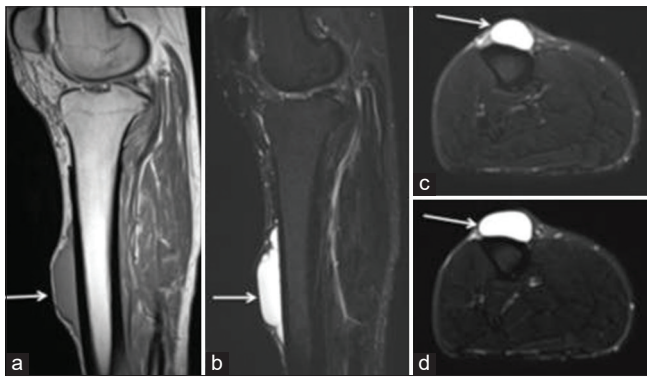


Figure 2: Sagittal T1 (a), STIR (b), and axial STIR (c and d) showing pretibial extraosseous ganglion (arrow).

the knee joint and pretibial ganglion cyst on delayed arthrographic images.^[6] These can mimic a tumor due to its atypical location.

The initial suspicion in our case was of a malignant tumor and was, therefore, referred to our oncology services. Following the biopsy, the lesion was significantly decompressed. Unfortunately, the patient presented 3 months later with recurrence, which was discussed at our multidisciplinary meeting and subsequently excised. The presence of recurrence suggests and supports the hypothesis that these invariables have communication with the knee joint, which may be obliterated and difficult to delineate on non-arthrographic MR images.

Pretibial hematoma, juxtacortical chondroma, osteosarcoma, infection, and pretibial varices are some of the lesions that can mimic a pretibial ganglion. Pretibial hematoma can be of varied signal on MR depending on age of hematoma. Juxtacortical chondroma is hypo- to isointense on T1 and high signal on T2. Infection is associated with marked osseous

and soft-tissue edema with or with intraosseous abscess depending on the stage of osteomyelitis. Osteosarcoma involves the metaphysis and is associated with marked periosteal reaction. The other differentials for pretibial lesions include granuloma annulare which is painless subcutaneous lesion in children that is low on T1 and heterogenous signal on T2. Cutaneous angioleiomyoma, soft-tissue sarcoma, and giant-cell tumors of the subcutaneous tissues are low on T1 and heterogenous to high on T2. Synovial sarcoma should also be considered which demonstrate heterogeneous signal on T2 with hemorrhage, calcification, and fluid levels. Rheumatoid nodule and Morel-Lavallee lesion are also in the differential. However a careful assessment of the lesion helps to clinch the diagnosis.

CONCLUSION

Pretibial ganglion should be considered while evaluating a pretibial lesion.

Declaration of patient consent

The authors certify that they have obtained all appropriate patient consent forms.

Financial support and sponsorship

Nil.

Conflicts of interest

There are no conflicts of interest.

REFERENCES

1. Deie M, Sumen Y, Ochi M, Murakami Y, Fujimoto E, Ikuta Y, *et al.* Pretibial cyst formation after anterior cruciate ligament reconstruction using auto hamstring grafts: Two case reports in a prospective study of 89 cases. *Magn Reson Imaging* 2000;18:973-7.
2. Malhan K, Kumar A, Rees D. Tibial cyst formation after anterior cruciate ligament reconstruction using a new bioabsorbable screw. *Knee* 2002;9:73-5.
3. Simonian PT, Wickiewicz TL, O'Brien SJ, Dines JS, Schatz JA, Warren RF, *et al.* Pretibial cyst formation after anterior cruciate ligament surgery with soft tissue autografts. *Arthroscopy* 1998;14:215-20.
4. Thauat M, Chambat P. Pretibial ganglion-like cyst formation after anterior cruciate ligament reconstruction: A consequence of the incomplete bony integration of the graft? *Knee Surg Sports Traumatol Arthrosc* 2007;15:522-4.
5. Victoroff BN, Paulos L, Beck C, Goodfellow DB. Subcutaneous pretibial cyst formation associated with anterior cruciate ligament allografts: A report of four cases and literature review. *Arthroscopy* 1995;11:486-94.
6. De Maeseneer M, De Boeck H, Shahabpour M, Hoorens A,

Oosterlinck D, Van Tiggelen R, *et al.* Subperiosteal ganglion cyst of the tibia. A communication with the knee demonstrated by delayed arthrography. *J Bone Joint Surg Br* 1999;81:643-6.

How to cite this article: Wigley C, Morris G, Evans S, Botchu R. A Case of an Extraosseous Pretibial Ganglion Cyst. *Indian J Musculoskelet Radiol* 2019;1(2):114-116.