

Original Article

MRI spectrum of avascular necrosis of femoral head in patients treated for COVID-19

Sushil Ghanshyama Kachewar¹, Smita Sushil Kachewar²

¹Department of Radiodiagnosis, Dr. Vikhe Patil Foundation's Medical College and Hospital, Ahmednagar, ²Department of Pathology, Deenanath Mangeshkar Hospital, Pune, Maharashtra, India.



***Corresponding author:**

Sushil Kachewar,
Department of Radiodiagnosis,
Dr. Vikhe Patil Foundation's
Medical College and Hospital,
Ahmednagar, Maharashtra,
India.

Received: 05 June 2021
Accepted: 22 March 2022
Epub Ahead of Print: 06 May 2022
Published: 23 June 2022

DOI

10.25259/IJMSR_33_2021

Quick Response Code:



ABSTRACT

Objectives: The objectives of the study were to analyze the spectrum of avascular necrosis (AVN) of the femoral head as seen in MRI images of patients treated for COVID-19.

Material and Methods: The different patterns of the findings of AVN of the femoral head as seen in MRI images in 200 patients who received standard treatment for COVID-19 in the recent past and presented with hip pain were analyzed retrospectively.

Results: No positive findings to suggest any femoral head AVN as per the Ficat and Arlet classification were seen in 94% of cases. Stage IV AVN was seen in 0 cases (0%). Stage I AVN was seen in 6 cases (3%). Stage II AVN was seen in 4 cases (2%). Stage III AVN was seen in 2 cases (1%).

Conclusion: In patients who have received standard treatment for COVID-19 and who later developed hip pain, the incidence of AVN was seen in 6% of cases. It was mainly seen more in the younger population (<40 years of age) probably due to quick ambulation and return to daily work. Elderly patients were rarely affected. Normal MRI findings were more common in these cases. Among the positive MRI scans of such cases, mild findings of AVN (Stage I) were the most predominant.

Keywords: COVID-19, Avascular necrosis, Femoral head, Steroid-induced avascular necrosis of the femoral head

INTRODUCTION

The occurrence of bone death following reduced blood supply or complete stoppage of blood supply is known as avascular necrosis (AVN). The affected bone portion then disintegrates and eventually collapses. The femur is one of the commonly affected bones. Excess use of corticosteroids is one of the most common medical causes of AVN. Affected patients usually complain of gradually increasing pain and reducing the range of movement. Treatment varies from guided physiotherapy to medications and eventually surgery if needed.^[1]

By May 28, 2021, a total of 168,599,045 confirmed COVID-19 cases, including 3,507,477 deaths, have been reported worldwide to the World Health Organization.^[2] Indian contribution to this global statistics has been 27,555,457 confirmed cases and about 318,895 deaths.^[3] However, no data pertaining to the occurrence or presentation of AVN in the femur of patients who have been treated for COVID-19 are available as of now.

This is an open-access article distributed under the terms of the Creative Commons Attribution-Non Commercial-Share Alike 4.0 License, which allows others to remix, transform, and build upon the work non-commercially, as long as the author is credited and the new creations are licensed under the identical terms.

©2022 Published by Scientific Scholar on behalf of Indian Journal of Musculoskeletal Radiology

Tremendous diagnostic data are available for diagnosing COVID-19 pneumonia, and numerous guidelines are being put forth for timely diagnosis and prompt treatment.^[4] However, diagnostic data and imaging guidelines for patients treated for COVID and suffering from hip pain are not available. Hence, this retrospective study was done to analyze the spectrum of AVN of the femoral head as seen in MRI images of patients treated for COVID-19.

MATERIAL AND METHODS

Patients and HIP MRI

This retrospective and observational study were approved by the Institutional Ethical Committee.

Patients, who had been treated for COVID-19 and developed hip pain within 6 months from January to May 2021, were included using the following criteria:

- Positive RT-PCR for SARS-CoV-2 obtained with nasopharyngeal/oropharyngeal swabs or COVID-19 positive on RAPID antigen test before starting treatment for COVID-19
- Received steroids during the treatment for COVID-19
- New-onset hip pain was not there before being affected by COVID-19
- MRI scan is done.

A total of 200 patients were included in the study between 20 and 70 years of age.

All patients were imaged using a multichannel 1.5 T GE MRI machine. Coronal 4 mm T1W FSE images were obtained using TE of 12.36. Other sequences for MRI hip-like T2W and STIR in axial as well as sagittal planes were also obtained, but T1W coronal images were along used for the present study due to wider acceptance and better demonstration of the suspected AVN.

The clinical, demographic, and imaging data of all the patients were recorded and various parameters were compared.

MRI image analysis

The following Ficat and Arlet classification system for MRI images was used for staging AVN of the femoral head.^[5]

- Stage 0: MRI: Normal
- Stage I: MRI shows edema
- Stage II: MRI: Geographic defect
- Stage III: MRI: Crescent sign and eventual cortical collapse
- Stage IV: MRI: End-stage with evidence of secondary degenerative change

Statistical analysis

Numerical data were expressed as a percentage (%) of the total. Relevant data were expressed in tabular form.

RESULTS

Demographic and clinical characteristics: These are listed in [Table 1]. Imaging features are shown in Figure 1.

Imaging features of MRI: These are listed in [Table 2].

The mean interval between the onset of initial symptoms and MRI was 2–4 weeks.

No positive findings to suggest any femoral head AVN as per the Ficat and Arlet classification were seen in 94% of cases.

- Stage IV AVN was seen in 0 cases (0%).
- Stage I AVN was seen in 6 cases (3%).
- Stage II AVN was seen in 4 cases (2%).
- Stage III AVN was seen in 2 cases (1%).

DISCUSSION

Globally, corticosteroids are being widely used for treating COVID-19 infection. Reports of high dose and/or long duration of steroid usage in these patients leading to steroid-induced AVN of the femoral head (SANFH) are on the rise. Hence, valid usage of steroids backed by the timely diagnosis of possible SANFH for its prevention and timely treatment is pertinent.^[6] SANFH has a poor prognosis as it can lead to a subchondral collapse in a short time.

Glucocorticoids affect the emulsification of very-low-density lipoprotein cholesterol in the blood which if incomplete adds to lipoprotein globules resulting in small fat emboli that occlude peripheral blood vessels cause ischemic necrosis of the bone tissue. Simultaneously, free fatty acids from hydrolysis of the fat emboli damage the capillary endothelial cells resulting in vasculitis and also encourage intravascular coagulation

Table 1: Demographic and clinical profile of the patients.

Criteria	Male	Female	Total
Gender	154	46	200
Symptoms			
Fever	15	10	025
Hip pain	150	43	193
Backache	084	34	118
Fatigue	140	34	174
Comorbidities			
Diabetes	05	07	12
Hypertension	06	11	17

Table 2: MRI staging characteristics in patients.

Features on MRI	n=200 (%)
Stage 0: Normal study: No abnormality	188 (94)
Stage 1: Edema in femoral head	06 (03)
Stage 2: Geographic defect in femoral head	04 (02)
Stage 3: Collapse of femoral head	02 (01)
Stage 4: Secondary changes of osteoarthritis	00 (00)

further speeding up the AVN.^[7] Glucocorticoids impair the response of the blood vessels to vasoactive substances causing vascular constriction affecting the femoral head causing further femoral head ischemia.^[8] MicroRNA (*miR*)-596 in cases diagnosed as SNFHN is found to be upregulated, thereby impairing the repair of the osteonecrotic bone as it inhibits the proliferation and osteogenic differentiation of the bone marrow stromal cells.^[9] *miR-17-5p* and *miR-210* are also believed to be involved in the pathogenesis of SANFH.^[10,11]

It has been reported that as many as, about 39% of patients with COVID-19 developed SIFHN in a few months of glucocorticoid treatment.^[12] In fact, few patients who were on corticosteroids for less than a month too or even at lesser doses as well reported AVN.^[13] Some studies implicate the virus itself as an independent factor leading to AVN through S protein *per se*.^[14,15]

It has been opined by recent researchers^[6] that patients with mild COVID-19 illness should not be administered corticosteroids. Only those having severe disease should be put on steroids that too as low dosage as needed for treatment. The level of dosage may vary from region to region and locality to locality.^[6]

As the recovery rate from COVID-19 is thankfully increasing, it has to be remembered that we would see more and more post-convalescence complications like AVN^[16] which can thereby significantly hamper the return to normalcy in such patients. Long-term follow-up and big data in this aspect are our current constraints; hence, the sooner we assess any new onset large joint pain in such patients the better we are in diagnosing and treating AVN.^[16]

Prompt diagnosis ensures timely treatment. Hence, periodic MRI scans for possible AVN of the hip, especially in high-risk patients, have been found to be 93–100% sensitive.^[17] It has been found that the onset time of post-glucocorticoid usage AVN can start occurring anywhere from 3 weeks to 3 months.^[18,19] MRI scans are recommended at 3, 6, and 12 months after steroid administration.^[20]

If left untreated, AVN becomes irreversible and damages the hip permanently. Some medications like levodopa reduce osteocyte apoptosis and enhance repair by increasing insulin-like growth factor-1.^[21] Alendronate sodium inhibits the bone resorption capacity of osteoclasts and delays AVN.^[22] Hyperbaric oxygen treatment for 6 weeks promotes angiogenesis and improves the function of osteoblasts and osteoclasts and gives symptomatic relief.^[23,24] An year of extracorporeal shock wave therapy (ESWT) was found to significantly reduce pain and improve functionality.^[25] Combined therapy (alendronate sodium, ESWT, and HBO) can delay and even prevent the development of AVN.^[26]

The present study assessed MRI hip imaging features in patients suffering from hip or back pain that had received

standard treatment for COVID-19 pneumonia in a sample of 200 patients.

No significant hip joint findings were noted in maximum cases 188/200 (94%). We found an abnormal (positive) MRI hip status in 12/200 (06%) of patients. Maximum patients presented between 2 and 4 weeks of symptoms of hip or back pain.

Stage IV AVN was seen in 0 cases (0%). This is because all the cases were detected earlier due to the timely presentation of affected patients. Stage I AVN was the most common and seen in 6 cases (3%). This represents edema. Most of the patients were in the younger age group <40 years and hence presented earlier.

Stage II AVN was seen in 4 cases (2%). This was seen more in the middle and elderly age group (40–60 years of age). Stage III AVN was seen in 2 cases (1%). This was seen more in the elderly age group (>60 years of age).

The most commonly affected age group in the present study was <40 years of age. It is likely that this particular age group after getting treated for COVID-19 returned to their office work and daily chores as they belonged to the active working-age group. Positive inclusion criteria but no positive findings on MRI scans in a large number of patients indicate that the patients underwent MRI in a very early phase so hip lesions were not developed till that time. It is also possible that though the patients had symptoms, they might not be due to problems in the hip *per se*.

The study highlights the necessity to be vigilant for the possibility of AVN of the hip in these cases so that they are timely diagnosed early on and treated properly as per prevalent scientific norms.

The study is limited by its small sample size and absence of follow-up scans. The exact amount and duration for which patients received steroid treatment during COVID-19 infection could not be ascertained. The radiological and histopathological correlation could not be established due to the wanting of femoral biopsy permissions. Furthermore, recently, reported BOLD-MRI which is of more usage in early detection of AVN over conventional MRI techniques^[27] could not be used for lack of availability.

Other limitations of the study

There is no doubt that information about the exact time duration of the appearance of the MRI findings and the time of COVID-19 inflection and relevant clinical histories such as smoking, other comorbidities, and weight of the patient would have added multivariate analysis to this study – but alas it could not be added as this was essentially a retrospective study given the tremendous workload during each wave.

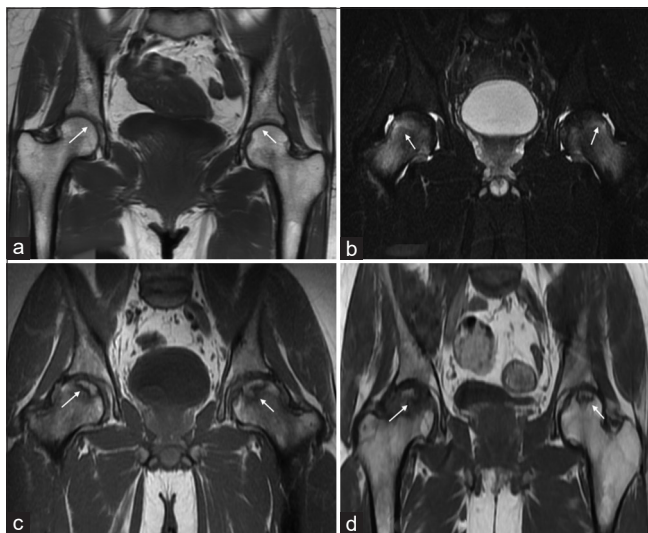


Figure 1: (a) Coronal MRI T1W image: Normal appearance of femoral heads, (b) coronal MRI STIR image: Bilateral Stage I AVN of femoral heads, (c) coronal MRI T1W image: Bilateral Stage II AVN of femoral head, and (d) coronal MRI T1W image: Right Stage III AVN of femoral head, left Stage II.

CONCLUSION

Newer data about evolving AVN of hips in patients that received treatment for COVID-19 in the recent past are emerging. Gradually, cases are bound to increase. Hence, the medical fraternity should be aware of this possibility and inform the patients about this entity for timely diagnosis and management.

Declaration of patient consent

Institutional Review Board (IRB) permission was obtained for the study.

Financial support and sponsorship

Nil.

Conflicts of interest

There are no conflicts of interest.

REFERENCES

- Shetty L, Nahar S, Domah T, Raj AT. COVID-19 patients could be at high risk for dry socket. *Med Hypotheses* 2021;146:110462.
- World Health Organization. WHO Coronavirus Disease (COVID-19) Dashboard WHO Coronavirus Disease (COVID-19) Dashboard. Geneva: World Health Organization. Available from: <https://covid19.who.int> [Last accessed on 2021 May 29].
- COVID-19 Tracker Updates For India For State Wise and District Wise Data. Available from: <https://covidindia.org> [Last accessed on 2021 May 29].
- Fang Y, Zhang H, Xie J, Lin M, Ying L, Pang P, *et al.* Sensitivity of chest CT for COVID-19: Comparison to RT-PCR. *Radiology* 2020;296:E115-7.
- Arlet J, Ficat RP. Forage-biopsie de la tete femorale dans l'osteonecrose primitive. Observations histopathologiques portant sur huit forances. *Rev Rheum* 1964;31:257-64.
- Zhang S, Wang C, Shi L, Xue Q. Beware of steroid-induced avascular necrosis of the femoral head in the treatment of COVID-19-experience and lessons from the SARS epidemic. *Drug Des Devel Ther* 2021;15:983-95.
- Koo KH, Kim R, Kim YS, Ahn IO, Cho SH, Song HR, *et al.* Risk period for developing osteonecrosis of the femoral head in patients on steroid treatment. *Clin Rheumatol* 2002;21:299-303.
- Kerachian MA, Séguin C, Harvey EJ. Glucocorticoids in osteonecrosis of the femoral head: A new understanding of the mechanisms of action. *J Steroid Biochem Mol Biol* 2009;114:121-8.
- Ligong F, Liu H, Lei W. MiR-596 inhibits osteoblastic differentiation and cell proliferation by targeting Smad3 in steroid-induced osteonecrosis of femoral head. *J Orthop Surg Res* 2020;15:173.
- Yamasaki K, Nakasa T, Miyaki S, Yamasaki T, Yasunaga Y, Ochi M. Angiogenic microRNA-210 is present in cells surrounding osteonecrosis. *J Orthop Res* 2012;30:1263-70.
- Jia J, Feng X, Weihua X, Yang S, Zhang Q, Liu X, *et al.* MiR-17-5p modulates osteoblastic differentiation and cell proliferation by targeting SMAD7 in non-traumatic osteonecrosis. *Exp Mol Med* 2014;46:e107.
- Hui L, de Vlas SJ, Liu W, Wang TB, Cao ZY, Li CP, *et al.* Avascular osteonecrosis after treatment of SARS: A 3-year longitudinal study. *Trop Med Int Health* 2009;14 Suppl 1:79-84.
- Shibatani M, Fujioka M, Arai Y, Takahashi K, Ueshima K, Okamoto M, *et al.* Degree of corticosteroid treatment within the first 2 months of renal transplantation has a strong influence on the incidence of osteonecrosis of the femoral head. *Acta Orthop* 2008;79:631-6.
- Hofmann H, Geier M, Marzi A, Krumbiegel M, Peipp M, Fey GH, *et al.* Susceptibility to SARS coronavirus S protein-driven infection correlates with expression of angiotensin converting enzyme 2 and infection can be blocked by soluble receptor. *Biochem Biophys Res Commun* 2004;319:1216-21.
- Ksiazek TG, Erdman D, Goldsmith CS, Zaki SR, Peret T, Emery S, *et al.* A novel coronavirus associated with severe acute respiratory syndrome. *N Engl J Med* 2003;348:1953-66.
- Namiranian P, Razavi SZ, Karim M, Ayati MH. Avascular necrosis in patients recovering from COVID-19. *Am J Med Sci* 2021;362:331-2.
- Tervonen O, Mueller DM, Matteson EL, Velosa JA, Ginsburg WW, Ehman RL. Clinically occult avascular necrosis of the hip: Prevalence in an asymptomatic population at risk. *Radiology* 1992;182:845-7.
- Kubo Y, Yamamoto T, Motomura G, Tsukamoto N, Karasuyama K, Sonoda K, *et al.* MRI-detected bone

- marrow changes within 3 weeks after initiation of high-dose corticosteroid therapy: A possible change preceding the subsequent appearance of low-intensity band in femoral head osteonecrosis. *Rheumatol Int* 2015;35:1909-12.
19. Xie XH, Wang XL, Yang HL, Zhao DW, Qin L. Steroid-associated osteonecrosis: Epidemiology, pathophysiology, animal model, prevention, and potential treatments (an overview). *J Orthopaedic Translat* 2015;3:58-70.
 20. Hong N, Du X, Nie Z, Sijun L. Diffusion-weighted MR study of femoral head avascular necrosis in severe acute respiratory syndrome patients. *J Magn Reson Imaging* 2005;22:661-4.
 21. Hongbo X, Tao W, Jian Z, Sun X, Gong X, Huang L, *et al*. Levodopa attenuates cellular apoptosis in steroid-associated necrosis of the femoral head. *Exp Ther Med* 2017;13:69-74.
 22. Hong YC, Luo RB, Lin T, Zhong MH, Shi JB. Efficacy of alendronate for preventing collapse of femoral head in adult patients with nontraumatic osteonecrosis. *Biomed Res Int* 2014;2014:716538.
 23. Camporesi EM, Vezzani G, Bosco G, Mangar D, Bernasek TL. Hyperbaric oxygen therapy in femoral head necrosis. *J Arthroplasty* 2010;25 Suppl 6:118-23.
 24. Koren L, Ginesin E, Melamed Y, Norman D, Levin D, Peled E. Hyperbaric oxygen for stage I and II femoral head osteonecrosis. *Orthopedics* 2015;38:e200-5.
 25. Ludwig J, Lauber S, Lauber HJ, Dreisilker U, Raedel R, Hotzinger H. High-energy shock wave treatment of femoral head necrosis in adults. *Clin Orthop Relat Res* 2001;387:119-26.
 26. Liu T, Jinchao M, Bin S, Wang H, Wang Q, Ma X. A 12-year follow-up study of combined treatment of post-severe acute respiratory syndrome patients with femoral head necrosis. *Ther Clin Risk Manag* 2017;13:1449-54.
 27. Li J, Wang J, Zhao J, Yuan B, Xing L, Tang F, *et al*. BOLD-MRI early detect femoral head osteonecrosis following steroid-treated patients. *Medicine (Baltimore)* 2017;96:e8401.

How to cite this article: Kachewar SG, Kachewar SS. MRI spectrum of avascular necrosis of femoral head in patients treated for COVID-19. *Indian J Musculoskelet Radiol* 2022;4:13-7.