

Original Article

## Role of High-Resolution Ultrasonography in Evaluation of Median Nerve and Thickness of Flexor Retinaculum in Patients with Hypothyroidism

Kunwar Pal Singh<sup>1</sup>, Kamlesh Gupta<sup>1</sup>, Iqbaljit Kaur<sup>1</sup>, Vijinder Arora<sup>1</sup>

<sup>1</sup>Department of Radiodiagnosis, Sri Guru Ram Das Institute of Medical Sciences and Research, Sri Amritsar, Mehta Road, Post Office Vallah, Amritsar, Punjab, India.



**\*Corresponding author:**

Kunwar Pal Singh,  
Department of Radiodiagnosis,  
Sri Guru Ram Das Institute  
of Medical Sciences and  
Research, Sri Amritsar,  
Mehta Road, Post Office Vallah,  
Amritsar - 143 501,  
Punjab, India.

kpsdhami@gmail.com

Received : 20 November 2019

Accepted : 18 April 2020

Published : 29 June 2020

DOI

10.25259/IJMSR\_45\_2019

Quick Response Code:



### ABSTRACT

**Objectives:** To determine the role of high resolution ultrasonography in evaluation of cross sectional area, maximum nerve fascicle thickness and thickness/width ratio of the median nerve and flexor retinaculum thickness in patients with hypothyroidism and to correlate it with the healthy volunteers.

**Material and Methods:** A prospective study was conducted from February 2018 to October 2019 on 62 patients which included 32 clinically proven cases of hypothyroidism and 30 healthy volunteers. High resolution ultrasonography was performed using high frequency linear probes.

**Results:** The most affected parameter was cross sectional area of median nerve at three levels, inlet/outlet ratio of CSA of the median nerve and thickness of flexor retinaculum in hypothyroidism patients in correlation with healthy volunteers. These parameters showed statistically significant p values. Maximum nerve fascicle thickness and thickness/width ratio of the median nerve showed no statistical significance in hypothyroid patients in correlation with healthy volunteers.

**Conclusion:** High-resolution ultrasonography plays an important role in evaluating the changes occurring in cross sectional area of the median nerve, its inlet/outlet CSA ratio and flexor retinaculum thickness in hypothyroidism patients as correlated with the healthy volunteers.

**Keywords:** Hypothyroidism, Median nerve, High resolution ultrasonography

### INTRODUCTION

Hypothyroidism is a clinical disorder due to the deficiency of the thyroid hormone. This hormone is a key regulator of cellular metabolism in our body. This deficient state is estimated to affect 3.8–4.6% of the general population, with a four-fold affection in women.

Peripheral nerve dysfunction is a well-documented feature of clinical hypothyroidism. Thyroid hormone deficiency causes sensory neuropathy by affecting different peripheral nerves, especially the median nerve. The mechanism involved in the development of neuropathy in hypothyroidism still remains unclear.<sup>[1]</sup>

Carpal tunnel syndrome (CTS) is the most frequent entrapment syndrome of the upper limb; it arises due to the compression of the median nerve at the wrist, which leads to an enlargement of the median nerve cross-sectional area (CSA). An early diagnosis based on clinical and electrodiagnostic findings is essential to prevent permanent nerve damage and functional sequelae.

This is an open-access article distributed under the terms of the Creative Commons Attribution-Non Commercial-Share Alike 4.0 License, which allows others to remix, tweak, and build upon the work non-commercially, as long as the author is credited and the new creations are licensed under the identical terms.

©2019 Published by Scientific Scholar on behalf of Indian Journal of Musculoskeletal Radiology

The pathologic mechanics observed in the carpal tunnel during activity suggest a multifactorial cause of CTS: Increased intracarpal pressure, decreased nerve mobility, nerve compression, increased stiffness of the synovium, and flexor retinaculum.

The most commonly described abnormality has been enlargement of the median nerve CSA usually proximal to the carpal tunnel.

Phalen's maneuver can also be used in an adjunctive manner in diagnosing CTS. High-resolution ultrasound and MRI have emerged as feasible, non-invasive imaging tools for evaluating the median nerve in the carpal tunnel.<sup>[2]</sup>

Ultrasonography has emerged as an important diagnostic investigation for CTS. A number of ultrasonographic changes have been demonstrated in CTS, including swelling of the median nerve, flattening of the nerve, palmar bowing and thickening of the flexor retinaculum, and changes in the median nerve appearance.<sup>[3]</sup>

## MATERIAL AND METHODS

### Study design

We conducted a prospective study of 62 patients which include 32 patients of hypothyroidism (Group A) and 30 healthy volunteers (Group B) each in the department of radiodiagnosis from February 2018 to October 2019 referred for ultrasonography by the outpatient department or who were admitted to the hospital. The inclusion criteria were Group A – patients with hypothyroidism and Group B – healthy volunteers. The exclusion criteria were all patients with peripheral neuropathy due to diabetes mellitus, obesity, pregnancy, alcohol, and drug induced.

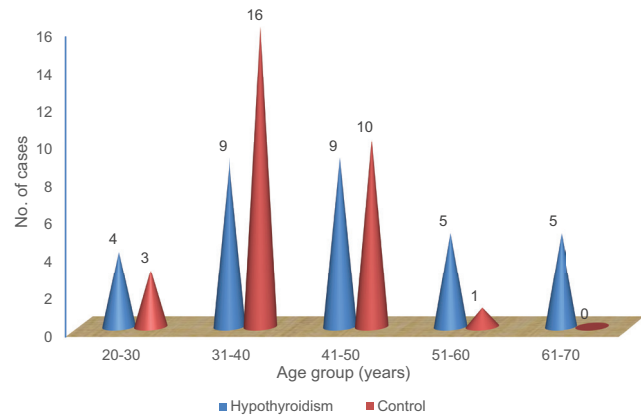
### Sonography technique

The high-resolution sonography was performed using Voluson E8 Expert BT09 (Wipro GE) with linear transducers of frequency 7–11 MHz and 7–18 MHz, Affiniti 50G (Phillips Healthcare) with linear transducer of frequency 4–12 MHz or Logiq P6 (Wipro GE) with linear frequency of 7–11 MHz.

## RESULTS

The study included 124 wrists of 62 patients, in which 32 patients were clinically proven cases of hypothyroidism and 30 healthy volunteers, and they underwent high-resolution ultrasonography after the clinical examination (Phalen's test) done in hypothyroidism patients. The total number of females was 53 and the males were 9. The ages ranged from 20 to 70 years with a mean age of 42 years.

The observations made during the study are summarized in Tables 1-7 and images are shown in Figures 1-8.



### Age-wise distribution of the subjects

Our study group consisted of both male and female patients with female preponderance.

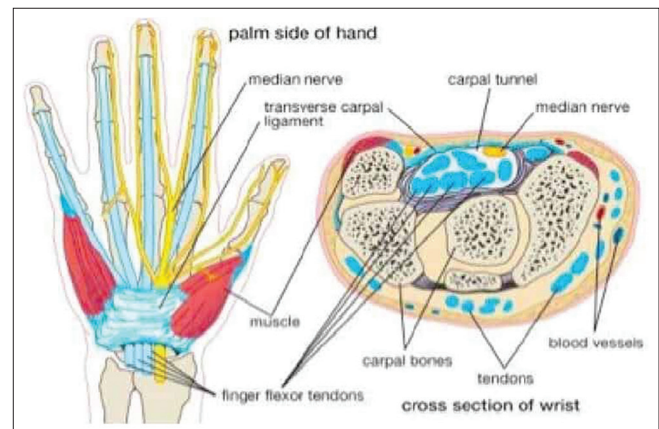
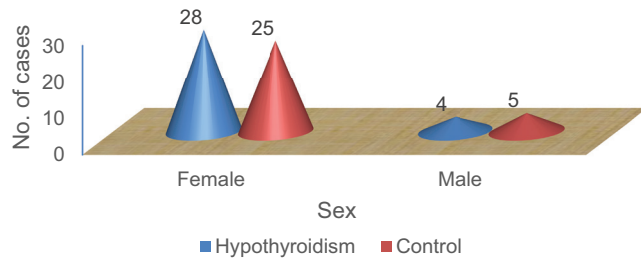


Figure 1: Anatomy of median nerve and flexor retinaculum.<sup>[4]</sup>

Table 1: Duration of disease.

Duration of disease (months)	Number of patients	% age
≤24	15	46.88
24–48	11	34.38
>48	6	18.75
Total	32	100.00
Mean duration of disease		29.09±19.29

**Table 2:** Ultrasound evaluation of the cross-sectional area, maximum nerve fascicle thickness, and thickness/width ratio of median nerve at the level of pronator quadratus.

Group	Cross-sectional area (cm <sup>2</sup> )					P-value
	Right forearm		P-value	Left forearm		
	Mean	SD		Mean	SD	
Hypothyroidism	0.064	0.053	0.031	0.062	0.022	0.042
Healthy	0.053	0.015		0.052	0.014	
Maximum nerve fascicle thickness (cm)						
Hypothyroidism	0.029	0.011	0.102	0.032	0.010	0.106
Healthy	0.025	0.007		0.024	0.006	
Thickness/width ratio						
Hypothyroidism	3.417	0.927	0.872	3.605	0.872	0.932
Healthy	3.455	0.931		3.586	0.902	

**Table 3:** Ultrasound evaluation of the cross-sectional area, maximum nerve fascicle thickness, and thickness/width ratio of median nerve proximal to carpal tunnel inlet.

Group	Cross-sectional area (cm <sup>2</sup> )					P-value
	Right forearm		P-value	Left forearm		
	Mean	SD		Mean	SD	
Hypothyroidism	0.074	0.022	0.014	0.073	0.024	0.034
Healthy	0.061	0.016		0.061	0.017	
Maximum nerve fascicle thickness (cm)						
Hypothyroidism	0.027	0.008	0.362	0.032	0.009	0.378
Healthy	0.025	0.007		0.024	0.006	
Thickness/width ratio						
Hypothyroidism	3.081	0.721	0.872	3.057	0.889	0.847
Healthy	3.057	0.428		3.021	0.481	

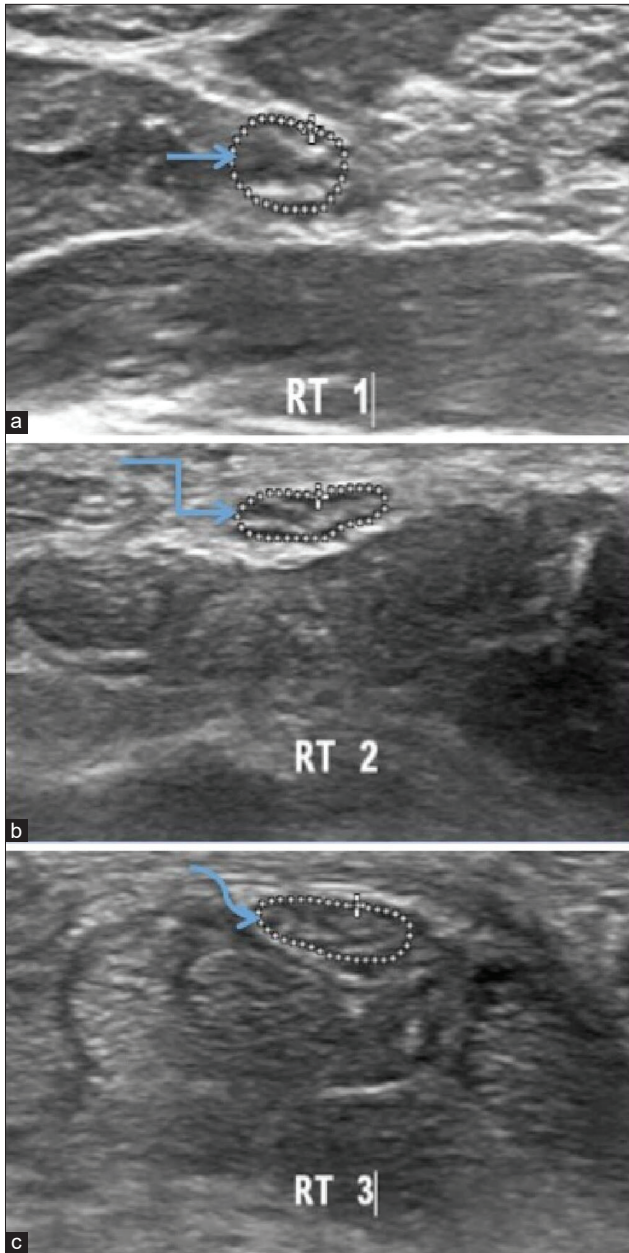
**Table 4:** Ultrasound evaluation of the cross-sectional area, maximum nerve fascicle thickness, and thickness/width ratio of median nerve distal to carpal tunnel outlet.

Group	Cross-sectional area (cm <sup>2</sup> )					P-value
	Right forearm		P-value	Left forearm		
	Mean	SD		Mean	SD	
Hypothyroidism	0.073	0.023	0.021	0.084	0.023	0.001
Healthy	0.061	0.016		0.067	0.015	
Maximum nerve fascicle thickness (cm)						
Hypothyroidism	0.031	0.010	0.371	0.032	0.009	0.506
Healthy	0.029	0.008		0.030	0.009	
Thickness/width ratio						
Hypothyroidism	2.699	1.031	0.504	2.606	0.908	0.973
Healthy	2.624	0.396		2.612	0.360	

**Table 5:** Ultrasound evaluation of the flexor retinaculum thickness.

Group	Flexor retinaculum (cm)					P-value
	Right forearm		P-value	Left forearm		
	Mean	SD		Mean	SD	
Hypothyroidism	0.058	0.013	0.001	0.059	0.012	0.022
Controls	0.048	0.010		0.051	0.014	

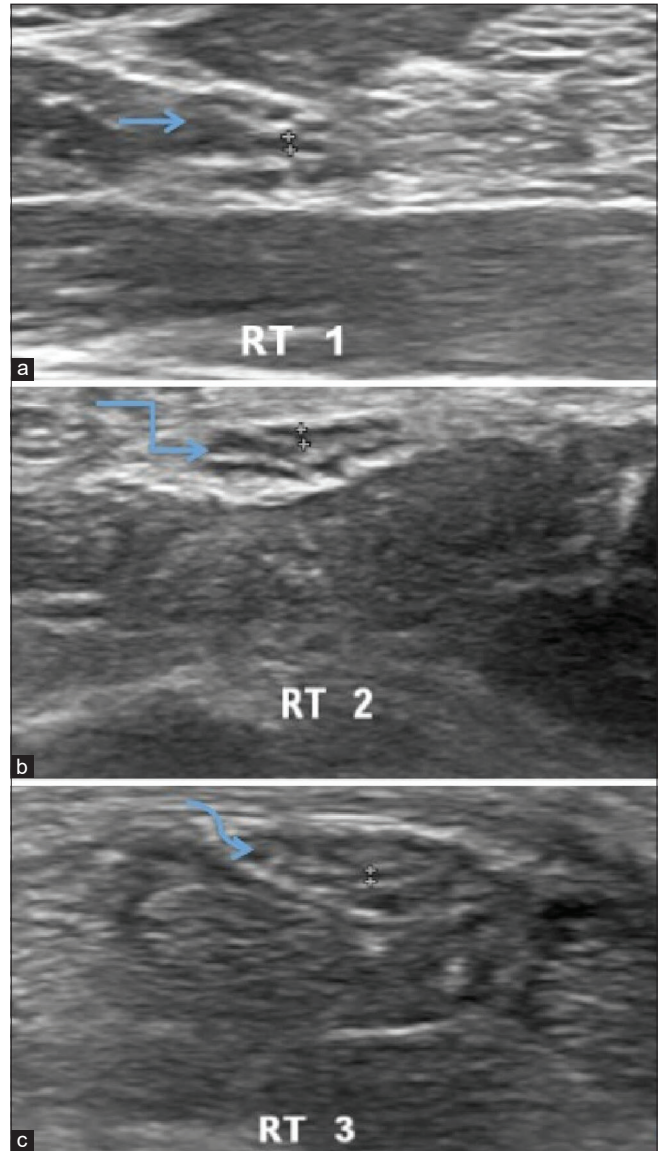




**Figure 2:** Ultrasonography image of the right median nerve of hypothyroidism patient at three levels in distal forearm showing (a) cross sectional area  $0.060 \text{ cm}^2$  at the level of pronator quadratus (straight arrow). (b) cross sectional area  $0.057 \text{ cm}^2$  proximal to the carpal tunnel inlet.(bent arrow) (c) cross sectional area  $0.053 \text{ cm}^2$  distal to the carpal tunnel outlet (curved arrow).

#### Distribution of subjects according to sex

The mean duration of disease was  $29.09 \pm 19.29$  years. Majority of the subjects were in the range of  $<24$  months, as shown in Table 1.



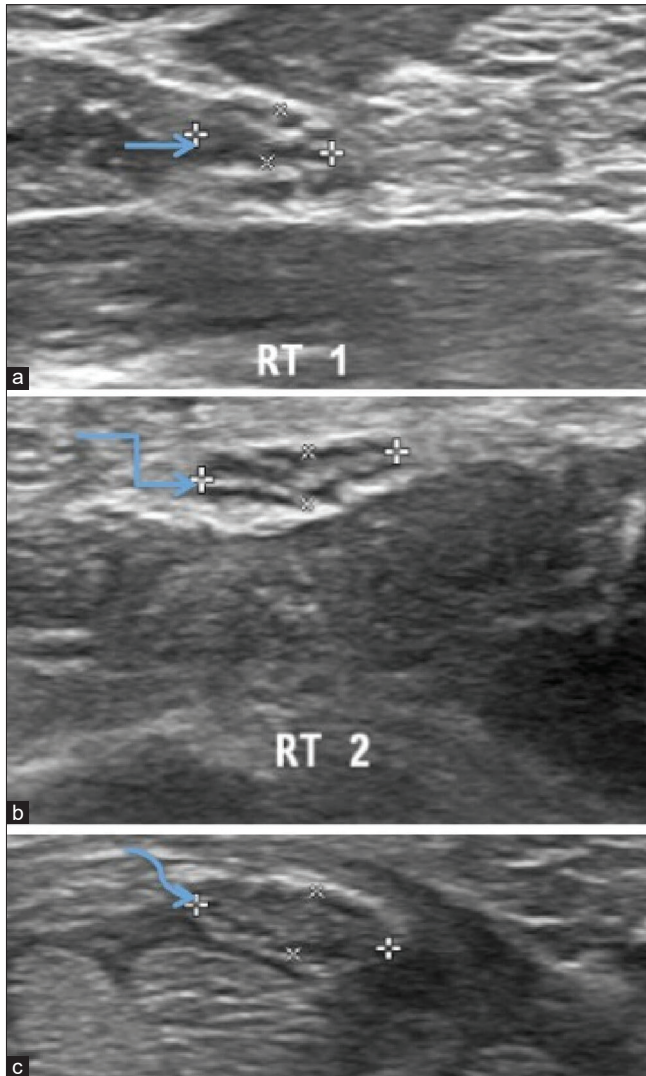
**Figure 3:** Ultrasonography of the Right median nerve of hypothyroidism patient showing hypoechoic median nerve fascicle thickness at three levels in distal forearm (a) Maximum thickness of nerve fascicle  $0.035 \text{ cm}$  at the level of pronator quadratus (straight arrow), (b) maximum thickness of nerve fascicle  $0.043 \text{ cm}$  proximal to carpal tunnel inlet (bent arrow), (c) maximum nerve fascicle thickness  $0.033 \text{ cm}$  distal to carpal tunnel outlet (curved arrow).

#### DISCUSSION

Ultrasound is effective in confirming the diagnosis of CTS. First, other lesions that display symptoms similar to CTS may be excluded from examination, and these include tenosynovitis, mass lesions, and anatomic defects. The use of US can be recommended as the first-line method in the diagnosis of CTS.<sup>[5-7]</sup>

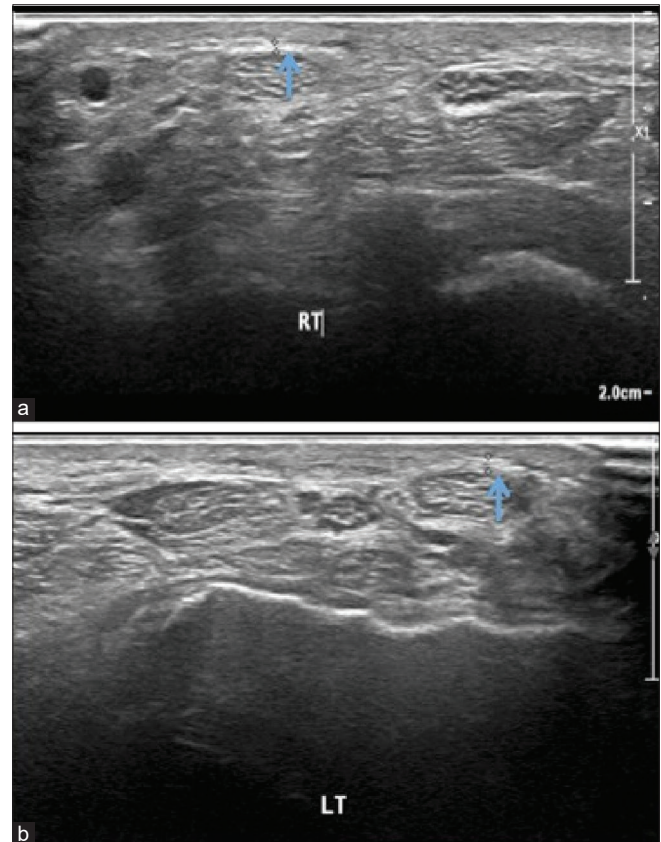
**Table 6:** Diagnostic value of inlet/outlet median nerve CSA ratio evaluated in hypothyroidism patients and healthy volunteers.

Group	Inlet/outlet CSA ratio					
	Right forearm		P-value	Left forearm		P-value
	Mean	SD		Mean	SD	
Hypothyroidism	0.975	0.185	0.009	0.932	0.141	0.001
Controls	0.865	0.132		0.821	0.124	



**Figure 4:** Ultrasonography of the Right median nerve of hypothyroidism patient showing thickness /width ratio at three levels in distal forearm (a) thickness/width ratio 2.59 at the level of pronator quadratus,(straight arrow) (b) thickness/width ratio 3.23 proximal to carpal tunnel inlet, (bent arrow) (c) thickness/width ratio 2.75 distal to carpal tunnel outlet.(curved arrow).

In our study, CSA of the median nerve has shown statistically significant at all three levels in both forearms in hypothyroid patients in correlation with healthy volunteers. Meyer *et al.* stated that an additional cross-sectional measurement at the



**Figure 5:** Ultrasonography image of the flexor retinaculum of hypothyroidism patient showing (a) thickness 0.07 cm on right side(arrow) and (b) 0.052 cm on left side(arrow).

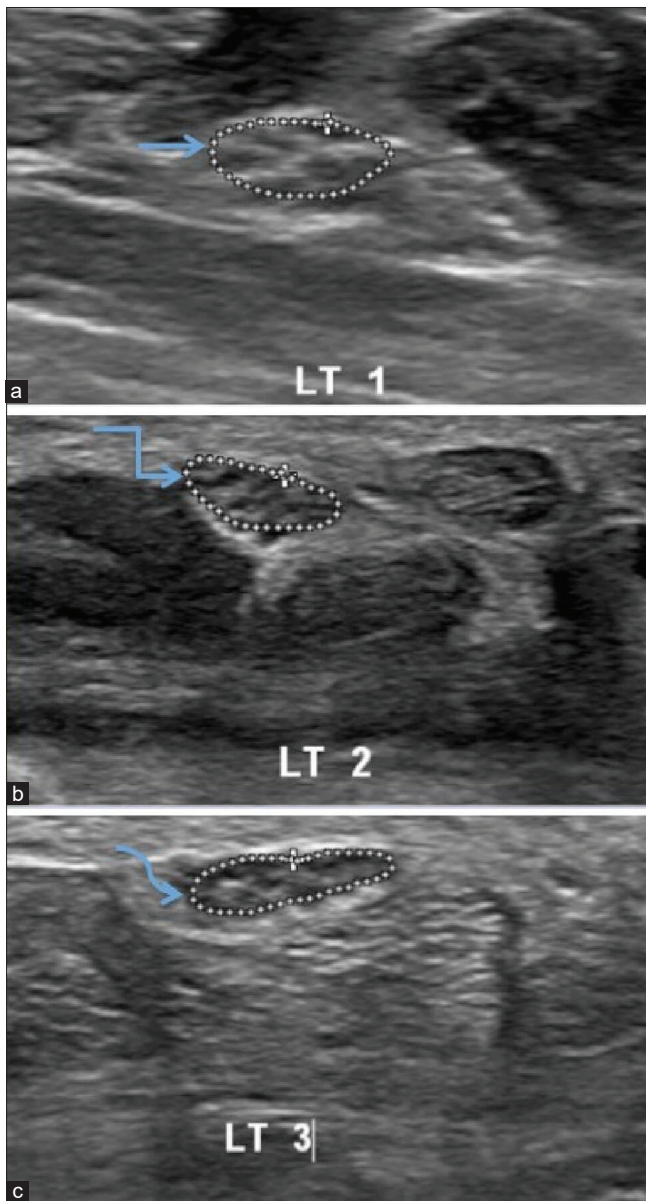
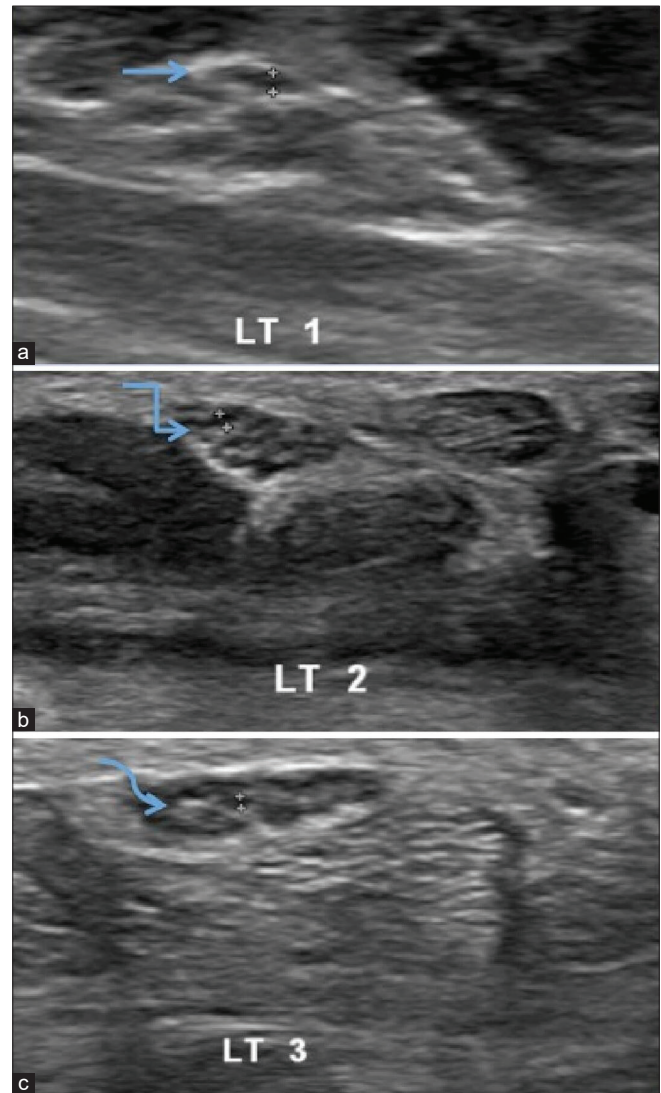
distal forearm with a calculation of the difference improves the diagnostic accuracy of US.<sup>[8]</sup> Wanitwattananurmlug *et al.* demonstrated that a quantitative assessment of the median nerve provides an accurate diagnostic test, with an area larger than 9 mm<sup>2</sup> being highly predictive of CTS.<sup>[9]</sup> Dana Holovacova *et al.* demonstrated the effect of hypothyroidism on the enlargement of the median nerve CSA.<sup>[10]</sup>

In the present study, the maximum thickness of the nerve fascicle was calculated by the largest anteroposterior dimension of the largest hypoechoic area in the short axis view of the median nerve.<sup>[11]</sup> The maximum nerve fascicle thickness and thickness/width ratio of the median nerve have not shown statistically significance in the right or left forearm in hypothyroid patients and healthy volunteers.

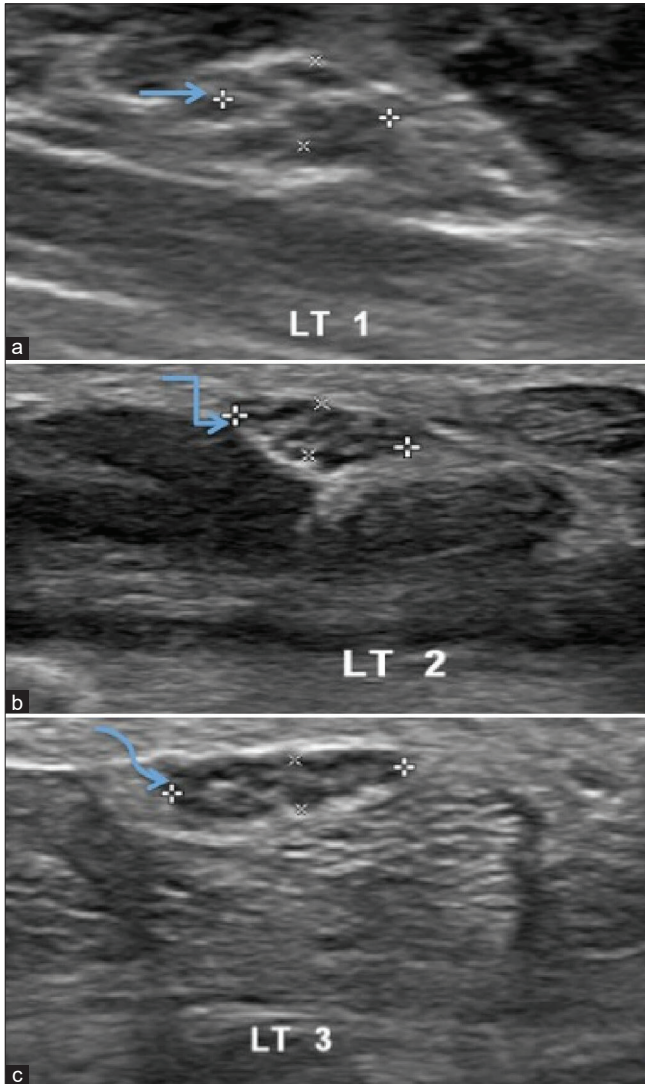


**Table 7:** Inlet/outlet CSA ratio of the median nerve is evaluated in hypothyroidism patients with positive Phalen's test and negative Phalen's test, respectively, in the right and left forearms.

Phalen's test	Inlet/outlet CSA ratio					
	Right forearm		P-value	Left forearm		P-value
	Mean	SD		Mean	SD	
Positive	0.988	0.213	0.029	0.928	0.160	0.032
Negative	0.884	0.135		0.816	0.122	

**Figure 6:** Ultrasonography image of the left median nerve of a healthy volunteer at three levels in distal forearm showing (a) cross sectional area 0.064 cm<sup>2</sup> at the level of pronator quadratus.(straight arrow) (b) cross sectional area 0.067 cm<sup>2</sup> proximal to the carpal tunnel inlet.(bent arrow) (c) cross sectional area 0.069 cm<sup>2</sup> distal to the carpal tunnel outlet.(curved arrow).**Figure 7:** Ultrasonography of the left median nerve of healthy volunteer showing hypoechoic median nerve fascicle thickness at three levels in distal forearm (a) Maximum thickness 0.041 cm at the level of pronator quadratus(straight arrow), (b) maximum thickness 0.050 cm proximal to carpal tunnel inlet(bent arrow), (c) maximum thickness 0.033 cm distal to carpal tunnel outlet (curved arrow).

In the present study, the thickness of flexor retinaculum shows statistical significance in both forearms in hypothyroid patients in correlation to healthy volunteers. Hence, ultrasound is



**Figure 8:** Ultrasonography of the left median nerve of healthy volunteer showing thickness /width ratio at three levels in distal forearm (a) thickness/width ratio 2.59 at the level of pronator quadratus,(straight arrow) (b) thickness/width ratio 3.03 proximal to carpal tunnel inlet, (bent arrow) (c) thickness/width ratio 2.89 distal to carpal tunnel outlet. (curved arrow).

valuable for future studies to detect subtle morphological changes of the flexor retinaculum thickness in that occur in hypothyroid patients. Shen and Li also demonstrate that ultrasound is useful in the assessment of flexor retinaculum.<sup>[12]</sup>

In the present study, the diagnostic value of the inlet/outlet CSA ratio of the median nerve was evaluated in patients with hypothyroidism and healthy volunteers in both forearms. The mean value was higher in hypothyroidism patients than healthy volunteers in the right and left forearms ( $P = 0.009$  in the right and  $0.001$  in the left forearm). The inlet/outlet CSA ratio of the median nerve promises to be an effective means in the diagnosis of the CTS in hypothyroidism patients.

Similar results were shown in a study by Fu *et al.*, in which they demonstrated that the inlet/outlet CSA ratio improves the diagnostic accuracy of ultrasound for the diagnosis of CTS.<sup>[13]</sup>

In our study, we also find that the mean value of the inlet/outlet CSA ratio of the median nerve was higher in Phalen's test positive patients than the Phalen's test negative patients in hypothyroidism group ( $P = 0.029$  in the right forearm and  $0.032$  in the left forearm). When the inlet/outlet CSA ratio was evaluated in hypothyroidism patients in correlation with healthy volunteers,  $P$  value was  $0.009$  and  $0.001$  in the right and left forearms, respectively, which was statistically significant. Hence, ultrasonography has a superior diagnostic value compared to Phalen's test in hypothyroidism patients.

Hence, CSA, inlet/outlet CSA of the median nerve, and thickness of flexor retinaculum in patients with hypothyroidism and healthy volunteers can be correlated. The maximum nerve fascicle thickness of median nerve and thickness/width ratio of the median nerve parameters are not of much useful parameter. Therefore, the CSA and inlet/outlet ratio of CSA came out to be significant in Phalen's test positive > Phalen's test negative hypothyroid patients > healthy volunteers.

## CONCLUSION

Ultrasound can be used for evaluation of the median nerve at three levels, inlet/outlet CSA ratio, and thickness of flexor retinaculum in hypothyroid patients. The high-resolution US allows direct imaging of the involved nerves, in addition to documentation of nerve shape changes that occur in compressive syndromes. It may be preferred by patients since it is easily accessible, non-invasive, shorter examination time, and of lower cost.

## Declaration of patient consent

Patient's consent not required as there are no patients in this study.

## Financial support and sponsorship

Nil.

## Conflicts of interest

There are no conflicts of interest.

## REFERENCES

1. Khamis OA, Altamimy HM, Abdellatif SS, Abdul-Hamied HI, Mostafa AA, Elayouty AE. Ultrasonography of median nerve in carpal tunnel syndrome before and after hormone replacement in patients with hypothyroidism. *Int J Radiol* 2015;2:66-71.

2. Hersh B, D'Auria J, Scott M, Fowler JR. A comparison of ultrasound and MRI measurements of the cross-sectional area of the median nerve at the wrist *Hand (NY)* 2018;14:746-50.
3. Deniz Y, Eda E, Filiz K. The effects of hypothyroidism on strength-duration properties of peripheral nerve. *J Neurol Sci* 2010; 294:89-91.
4. Kapusta S. Carpal tunnel syndrome physiology. In: *Encyclopaedia Britannica*. United Kingdom: Encyclopædia Britannica, Inc; 2007.
5. Kok-Yu C, John G, Khean-Jin G, Tunku SA. Ultrasonography in the evaluation of carpal tunnel syndrome: Diagnostic criteria and comparison with nerve conduction studies. *Neurol Asia* 2011;16:57-64.
6. Ghasemi-Rad M, Nosair E, Vegh A, Mohammadi A, Akkad A, Lesha E, *et al.* A handy review of carpal tunnel syndrome: From anatomy to diagnosis and treatment. *World J Radiol* 2014;6:284-300.
7. Mehrpour M, Mirzaasgari Z, Rohani M, Safdarian M. Diagnostic value of median nerve ultrasonography for screening of carpal tunnel syndrome in hypothyroid patients: A cross-sectional study. *Iran J Neurol* 2016;15:70-4.
8. Meyer P, Lintingre PF, Pesquer L, Poussange N, Silvestre A, Dallaudière B. The median nerve at the carpal tunnel and elsewhere. *J Belg Soc Radiol* 2018;102:17.
9. Wanitwattananurmlug B, Varavithya V, Aramrussameekul W. Evaluating the Cross-Sectional Area (CSA) of the Median Nerve by Use of Ultrasound in carpal tunnel syndrome (CTS). Nakhon Nayok: European Society of Radiology; 2011. p. 1-6.
10. Holovacova D, Kuzma M, Killinger Z, Payer J. Cross-sectional area of the median nerve is increased in primary autoimmune hypothyroidism and decreases upon treatment with thyroxine. *Eur J Endocrinol* 2016;175:265-71.
11. Singh K, Gupta K, Kaur S. High resolution ultrasonography of the tibial nerve in diabetic peripheral neuropathy. *J Ultrason* 2017;17:246-52.
12. Shen ZL, Li ZM. Ultrasound assessment of transverse carpal ligament thickness: A validity and reliability study. *Ultrasound Med Biol* 2012;38:982-8.
13. Fu T, Cao M, Liu F, Zhu J, Ye D, Feng X, *et al.* Carpal tunnel syndrome assessment with ultrasonography: Value of inlet-to-outlet median nerve area ratio in patients versus healthy volunteers. *PLoS One* 2015;10:e0116777.

**How to cite this article:** Singh KP, Gupta K, Kaur I, Arora V. Role of High-Resolution Ultrasonography in Evaluation of Median Nerve and Thickness of Flexor Retinaculum in Patients with Hypothyroidism. *Indian J Musculoskelet Radiol* 2020;2(1):36-43.