

Case Report

Displaced Labral Anchor – An Unusual Cause of Hip Pain with Arthroscopic Correlation

Rajesh Botchu¹, Angelos Politis², Steve James¹

Departments of ¹Musculoskeletal Radiology, ²Young Adult Hip, Royal Orthopedic Hospital, Birmingham, England.



*Corresponding author:

Dr. Rajesh Botchu,
Department of Musculoskeletal Radiology, The Royal Orthopedic Hospital Bristol Road South, Northfield, Birmingham, UK.
drbrajesh@yahoo.com

Received : 26 July 19
Accepted : 05 August 19
Published : 18 August 19

DOI
10.25259/IJMSR_11_2019

Quick Response Code:



ABSTRACT

Arthroscopic labral repair is a frequently performed procedure for symptomatic labral tears. Recurrent pain postoperatively may be due to the failure of the repair or anchor detachment. We report the imaging features of a displaced anchor with arthroscopic correlation.

Keywords: Labral, Repair, Displaced, Anchor

INTRODUCTION

The use of hip arthroscopy has significantly increased over the past two decades and can be considered the treatment of choice in the management of labral tears.^[1] Labral repairs are performed to decrease the risk of long-term joint degeneration. The risks of arthroscopy include deep vein thrombosis, neurovascular injury, and chondral damage.^[1,2] Recurrent pain post-arthroscopy can be due to a number of causes including recurrent labral tears, progressive chondral damage, and post-operative adhesions.^[3,4] Magnetic resonance (MR) is the modality of choice in the evaluation of symptomatic patients post-arthroscopy. We describe the MR imaging appearances of detached anchor resulting in recurrent pain, which was managed arthroscopically, and believe this to be the first reported case in literature with MR and arthroscopic correlation.

CASE REPORT

A 30-year-old fit and well female underwent arthroscopic labral repair, cartilage stabilization, and CAM debridement of the right hip for a symptomatic labral tear [Figure 1]. The labral repair was performed using SpeedLock Hip Knotless Fixation (Smith and Nephew) and Ultrabraid suture (Smith and Nephew). The initial treatment response was good, with near-total resolution of symptoms for 16 months. Subsequently, she noticed a sudden increase in symptoms with recurrence of groin pain. There was no history of trauma, but she had performed unaccustomed strenuous activities in the few weeks before symptom onset. A repeat MR was performed which revealed a loose body lying within the superolateral aspect of the right hip joint [Figure 2]. The loose body showed as a uniform low signal on all sequences with susceptibility artifact. The size and shape indicated this likely to be a detached anchor. Following discussion at our young adult hip multidisciplinary meeting, she underwent

This is an open-access article distributed under the terms of the Creative Commons Attribution-Non Commercial-Share Alike 4.0 License, which allows others to remix, tweak, and build upon the work non-commercially, as long as the author is credited and the new creations are licensed under the identical terms.

©2019 Published by Scientific Scholar on behalf of Indian Journal of Musculoskeletal Radiology

revision hip arthroscopy. During this, the anterior anchor was found to be well embedded in the acetabulum; however, the posterior anchor had pulled out and was within the hip joint and was removed. Due to the degenerate nature of the labrum, the patient underwent a labral debridement [Figure 3].

DISCUSSION

The labrum provides stability to the hip by increasing the volume and depth.^[5]

Labral tears can be due to trauma, femoroacetabular impingement, dysplasia, or degeneration. These typically

present with groin pain with occasional clicking and locking.^[6] High-resolution MR or MR arthrography is used to evaluate the labrum preoperatively.^[2] Labral tears can be managed non-operatively or by arthroscopic repair or debridement [Figures 4 and 5]. Hip arthroscopy was introduced in 1931 and there has been 4-fold increase in hip arthroscopies over the past two decades.^[7,8] Improvement of symptoms can be expected in almost 90% of patients.^[7] The complication rate of hip arthroscopy is 1.4–2.5% which include neurovascular injury, chondral damage, and deep vein thrombosis.^[2,9]

Failure of anchors in hip arthroscopy is not a rare occurrence, but only few reports exist in literature. Byrd *et al.* reported a 1.6% incidence of failure due to pull out in a series of 2007 all-suture anchors.^[3] The type of anchor in this series is different to the one reported here. A biomechanical study showed that all knotless suture anchors can fail under a single axial load, but every anchor system is performing differently in terms of biomechanical parameters such as stiffness, displacement, or maximum load.^[9]

The sutures and anchors can be radiolucent or radio-opaque depending on the material of composition. In this case, they are radiolucent and hence the position cannot be identified on radiographs. The location and position can be readily appreciated on CT or MR. On MR, the anchor appears as low signal on all sequences. The anchors should be positioned deep to the subchondral bone and protrusion can result in chondral damage, mechanical irritation, and subsequent pain. In symptomatic patient following hip

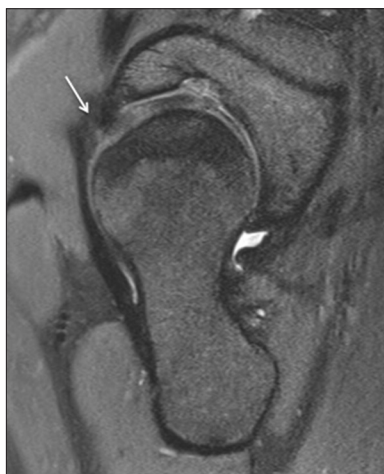

Figure 1: PDFS sag oblique showing an anterior labral tear (arrow).

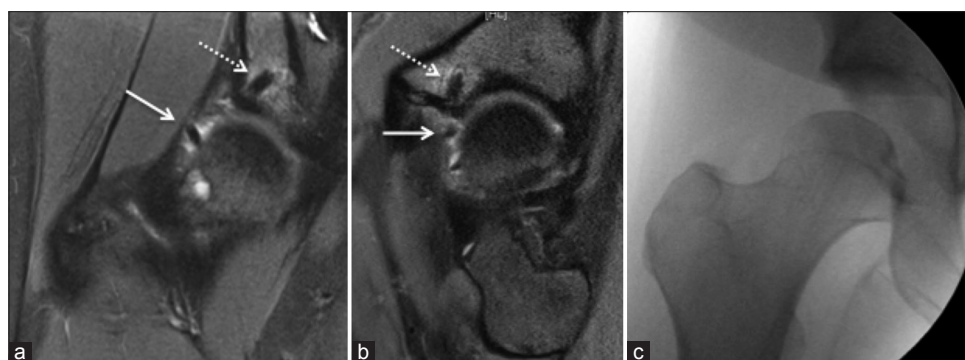


Figure 2: PDFS coronal oblique (a) and sag oblique (b) showing intact anchor (dotted arrow) and detached anchor (arrow). Note that AP fluoroscopy of the right hip (c) does not show the anchor (radiolucent).

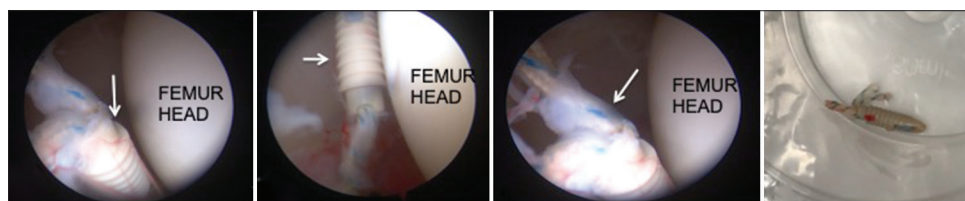


Figure 3: Arthroscopic images showing the detached anchor (arrow).

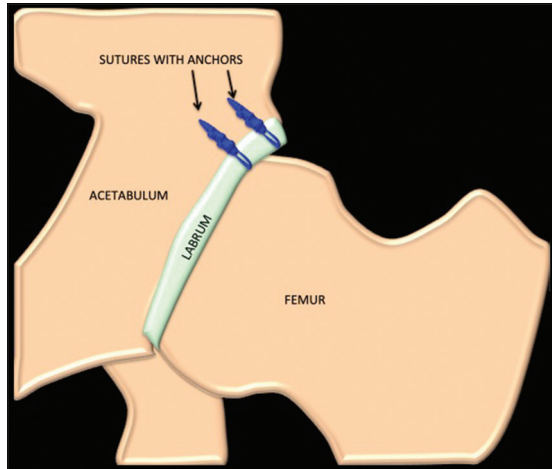


Figure 4: Diagrammatic representation of hip joint with labral repair.

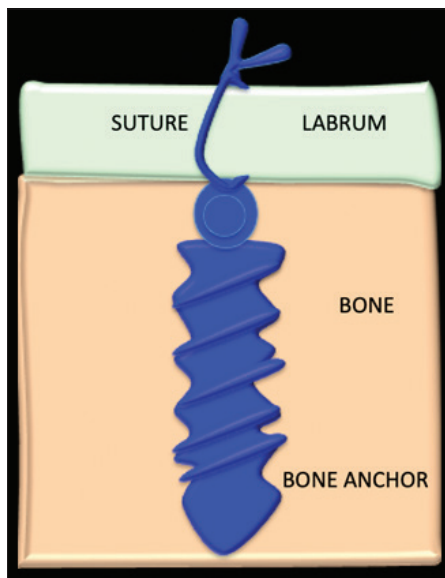


Figure 5: Diagrammatic representation of bone anchor and suture.

arthroscopy, MR imaging is the modality of choice. The site of surgery needs to be evaluated and anchor position should be carefully assessed. In this case, we describe the displacement of the anchor, effectively acting as a loose body in the hip joint.

It should be recognized that more subtle anchor displacement where they have backed out of the optimum position can be extremely challenging to evaluate on MR. Indeed, this may only be identified during direct visualization at arthroscopy.

CONCLUSION

We describe an rare cause of postoperative hip pain due to displaced anchor. One should assess the position of the anchors while evaluating MR of postoperative hip.

Declaration of patient consent

The authors certify that they have obtained all appropriate patient consent forms. In the form, the patient(s) has/have given his/her/their consent for his/her/their images and other clinical information to be reported in the journal. The patients understand that their names and initials will not be published and due efforts will be made to conceal their identity, but anonymity cannot be guaranteed.

Financial support and sponsorship

Nil.

Conflicts of interest

There are no conflicts of interest.

REFERENCES

1. Gao G, Zhang X, Xu Y, Wang J. Clinical outcomes and causes of arthroscopic hip revision surgery. *Sci Rep* 2019;9:1230.
2. Groh MM, Herrera J. A comprehensive review of hip labral tears. *Curr Rev Musculoskelet Med* 2009;2:105-17.
3. Byrd JW, Jones KS, Loring CL, Sparks SL. Acetabular all-suture anchor for labral repair: Incidence of intraoperative failure due to pullout. *Arthroscopy* 2018;34:1213-6.
4. Matsuda DK, Bharam S, White BJ, Matsuda NA, Safran M. Anchor-induced chondral damage in the hip. *J Hip Preserv Surg* 2015;2:56-64.
5. Harris JD. Hip labral repair: Options and outcomes. *Curr Rev Musculoskelet Med* 2016;9:361-7.
6. Burnett RS, Rocca GJ, Prather H, Curry M, Maloney WJ, Clohisy JC, *et al.* Clinical presentation of patients with tears of the acetabular labrum. *J Bone Joint Surg Am* 2006;88:1448-57.
7. Dorrell JH, Catterall A. The torn acetabular labrum. *J Bone Joint Surg Br* 1986;68:400-3.
8. Shenoy K, Dai AZ, Mahure SA, Kaplan DJ, Capogna B, Youm T, *et al.* Arthroscopic repair of hip labrum with suture anchors. *Arthrosc Tech* 2017;6:e2143-9.
9. Safran MR, Behn AW, Botser IB, Mardones R. Knotless anchors in acetabular labral repair: A Biomechanical comparison. *Arthroscopy* 2019;35:70-60.

How to cite this article: Botchu R, Politis A, James SL. Displaced Labral Anchor – An Unusual Cause of Hip Pain with Arthroscopic Correlation. *Indian J Musculoskelet Radiol* 2019;1(1):61-63.