




## Case Report

# Its not good to be too bossy - Carpal bossing: A case report with review of literature

Ashok Narayan S.H.<sup>1</sup> , Niveditha Raj<sup>1</sup>, Darshan Grewal<sup>1</sup> , Samaresh Sahu<sup>2</sup> 

Departments of <sup>1</sup>Radiology and <sup>2</sup>Radiodiagnosis and Imaging, Armed Forces Medical College, Pune, Maharashtra, India.



### \*Corresponding author:

Niveditha Raj,  
Department of Radiology,  
Armed Forces Medical College,  
Pune, Maharashtra, India.  
niveditharaj90@gmail.com

Received: 20 January 2022  
Accepted: 09 October 2022  
Epub Ahead of Print: 19 December 2022  
Published: 21 December 2022

DOI  
10.25259/IJMSR\_3\_2022

Quick Response Code:



## ABSTRACT

A 27-year-old male boxer presented with pain in the dorsum of the right wrist and difficulty in getting a firm grip on his hand for a 2-month duration. On examination, he had swelling over the dorsal aspect of the right wrist. Physical examination revealed a bony hard mass at the junction of the third metacarpal and capitate bones. The pain persisted despite conservative treatment and the patient was referred to our hospital for further evaluation. Radiographs of the right wrist posteroanterior and lateral views showed an accessory bone projecting from the base of the third metacarpal. The patient was evaluated on a multidetector computed tomography scan, which showed a bony protuberance arising from the dorsal aspect of the base of the third metacarpal showing continuation with the parent bone. No osteophyte/fracture of the bone could be appreciated. On magnetic resonance imaging, marrow edema was noted in the bony protuberance with edema in the overlying soft tissues. The patient underwent third metacarpal boss excision. At present, the patient is asymptomatic and is on regular follow-up.

**Keywords:** carpal bone, carpal bossing, accessory bone wrist, sports injury wrist, case report.

## INTRODUCTION

The carpal boss is a relatively uncommon entity. It is seen as a hard bulge at the dorsum of the wrist at the level of the trapezoid, capitate, and at the second or third metacarpal intersection.<sup>[1]</sup> It can lead to discomfort, pain, and an impediment to the movement of the affected hand. This projection can be due to auxiliary osteophyte and or due to an os styloideum- which is an unfused accessory ossification center. The ossicle is found dorsally between the second and third metacarpals and was first described by Saltzman in 1725.<sup>[2]</sup> French specialists Fiolle and Ailland depicted carpal bossing as a separate entity in French writing in 1932.<sup>[3]</sup> They at first depicted the substance as an asymptomatic exostosis emerging from the base of second and third metacarpals. Fiolle himself had this pathology, and he named the distortion as carpe bossu, or carpal bossing.<sup>[1]</sup> The accessory bone more often than not fuses with the second or third metacarpal base and every so often with the capitate or trapezoid. In roughly 25% of cases, the accessory bone remains partitioned and remains an extra ossicle – os styloideum.

## CASE REPORT

A 27-year-old male boxer presented with pain in the dorsum of the right wrist and difficulty in getting a firm grip on his hand for a 2-month duration. On examination, he had swelling over the dorsal aspect of the right wrist. The swelling had been present for several years but had caused no

symptoms until 2 months before admission when the patient had an injury while boxing. Physical examination revealed a bony hard mass at the junction of the third metacarpal and capitate bones. On movement of the middle finger, the extensor tendon overlying the swelling would slide over it, aggravating his pain. The pain persisted despite conservative treatment and the patient was referred to our hospital for further evaluation.

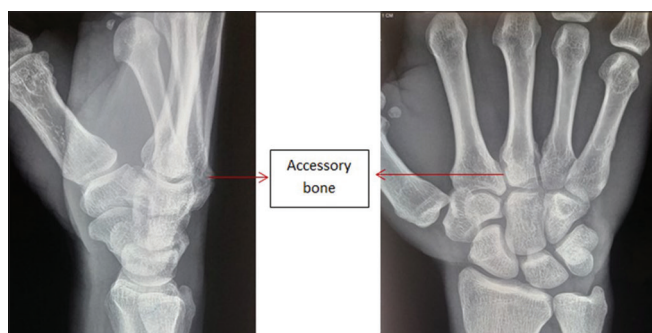
Radiographs of the right wrist posteroanterior (PA) and lateral views [Figure 1] showed an accessory bone projecting from the base of the third metacarpal. No obvious soft-tissue swelling could be appreciated. The patient was evaluated with non-contrast computed tomography (CT) scan using a 16 slice multidetector CT machine (Siemens Emotion 16; Erlangen; Germany), which revealed a bony protuberance arising from the dorsal aspect of the base of the third metacarpal which had continuation with the parent bone [Figures 2 and 3]. No carpal coalition, osteophyte formation, or evidence of old fracture could be appreciated. Magnetic resonance imaging (MRI) was performed on a 1.5 Tesla scanner (Siemens Magnetom

Symphony Syngo, Erlangen; Germany) using a flex coil. The T1W images showed a bony protuberance arising from the dorsal aspect of the base of the third metacarpal. The bone was lying at the interface of the trapezoid, capitate, and third metacarpal. On STIR and PDFS sequences, marrow edema was noted in the bony protuberance with edema in the overlying soft tissues – possibly attributing to and explaining the pain [Figure 4]. However, the Extensor Carpi Radialis Brevis (ECRB) tendon overlying the bone did not show any signal change.

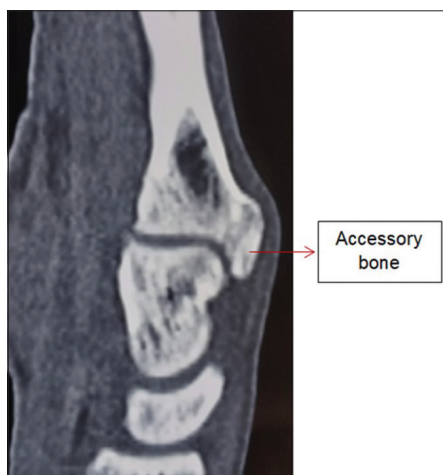The patient was managed with the excision of the metacarpal boss at the base of the third metacarpal [Figure 5]. He had an uneventful post-operative recovery. At present, the patient is asymptomatic and is on regular follow-up.

## DISCUSSION

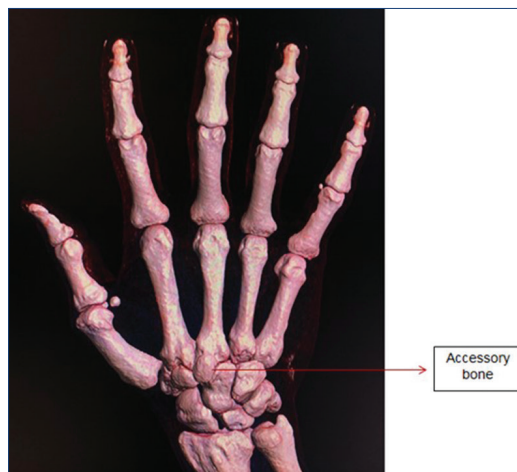
Carpal bossing ordinarily presents within the 2<sup>nd</sup>–4<sup>th</sup> decades of life. No sex prevalence is noted. This entity is seen in around 8–26% of the common populace with bilateral affliction in



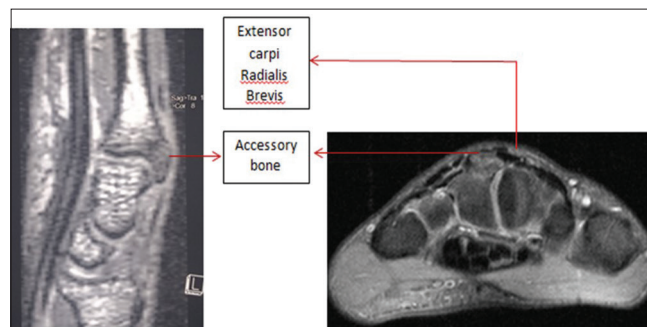
**Figure 1:** Radiograph right wrist posteroanterior and lateral views showing accessory bone projecting from the base of the third metacarpal.



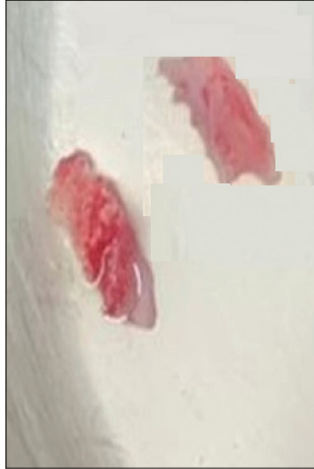**Figure 2:** Representative sagittal reconstructed computed tomography image showing the bony protuberance arising from the dorsal aspect of the base of the third metacarpal.



**Figure 3:** Representative 3D VRT reconstruction image showing the bony protuberance arising from the dorsal aspect of the base of the third metacarpal.



**Figure 4:** Representative flash 3D sagittal and axial T2W fat suppressed image showing the bony protuberance arising from the dorsal aspect of the base of the third metacarpal. The extensor Carpi Radialis Brevis tendon is in close approximation with the bone. However, the tendon does not show any change in signal intensity.



**Figure 5:** Post-operative resected specimen of the carpal boss.

up to 21% of the patients.<sup>[4]</sup> Wrist of the dominant hand is commonly affected by this condition.<sup>[2]</sup> Symptomatology may be due to the formation of a ganglion or inflamed bursa which is formed over the irregular bone. The extensor tendon slipping over the bony prominence can cause pain. The precise etiology of this entity is not known. Acquired causes are more common than congenital ones. Repeated minor trauma contributes to the symptomatology. Another theory is that injury causes a slight break of the dorsal ligament of the included joint with ensuing spur formation. Several cases have been reported in people with occupations requiring frequent movements of the fingers, such as typists, needle workers, specialists, knitters, and woodcarvers.<sup>[3]</sup> Other proposed theories of bony projection are a history of fracture in childhood, minor trauma leading to rupture of the dorsal ligament, periostitis at the level of the tendinous insertion of extensor carpi radialis, or an overgrowth of bone in response to abnormal stress, an osteophyte or an exostosis.<sup>[6]</sup> The major axis of stress in the normal wrist is in the region of the second and third metacarpals, the capitate, and the scapholunate joint. As most individuals are right-handed, the carpal boss happens more habitually within the right wrist.<sup>[1]</sup>

They are frequently unexpectedly identified while being assessed for other pathologies – especially using advanced imaging such as CT and MRI. They are usually asymptomatic. When symptomatic, it is called a carpal boss syndrome.<sup>[7]</sup> The regular complaint, on the off chance that any, is mild pain and fatigability of the wrist. There may be a clicking sensation due to slipping of the extensor tendon over the boss.

Clinical examination reveals a small bony prominence on the dorsal aspect of the wrist over the third carpometacarpal joint. The most common swelling in this region is a ganglion cyst. Carpal bossing is usually located proximally in the carpometacarpal joint and has a hard consistency, thereby distinguishing it from a ganglion cyst which has a soft to a

firm consistency. The other differentials at this site include localized fibrosis or subcutaneous calcification.<sup>[2]</sup>

X-rays, USG, CT, and MRI can be used for the evaluation of suspected carpal bossing.

Routine PA and lateral views may often miss this entity. There are two different radiological projections described for the diagnosis of carpal bossing: The Cuono view (or Carpal Boss view) (modified lateral view with the hand supinated (30–40°) and in a 20–30° ulnar deviation) and the carpal bridge view (90° palmar flexion of the wrist, dorsal side of the hand on the film and a 45° beam angulation in superoinferior direction toward the wrist). Carpal bossing appears as a bony overgrowth of the dorsal aspect of both the capitate and the third metacarpal bones at the joint margins, producing a characteristic double beak or bossing.<sup>[3]</sup> Cuno's view is considered a reliable and easier way to assess for the pathology.<sup>[2,8]</sup> However, the soft-tissue assessment is poor in radiography.

Ultrasound using high-frequency probes will help to assess the tendon insertion of the Extensor Carpi Radialis Longus, ECRB, and the external outline of some of the dorsal ligaments. Furthermore, ganglion cysts can be well assessed. Active inflammation can be detected by spectral Doppler. The continuity of the accessory bone with the parent bone can also be depicted by high frequency probes.

CT and MRI best characterize the relationship of the accessory bone to the carpometacarpal junction. They can demonstrate coalition, discriminate osseous fusion from an unfused os styloideum, and can even distinguish pseudarthrosis formation from joint degeneration. On MRI, bone marrow edema signal may correlate with clinical symptoms.<sup>[9]</sup> MRI can also depict a ganglion cyst or ECRB tenosynovitis. According to a study done by Mespreuve *et al.*, sectional imaging makes a difference in visualizing 25% of extra accessory bones that got missed by radiography.<sup>[10]</sup> Another included advantage of MRI is the superior evaluation of soft tissues. Post-contrast study can illustrate synovial thickening and enhancement. MR arthrography can delineate lesions involving dorsal ligaments or a ruptured tendon at the insertion of Extensor Carpi Radialis Longus and ECRB.

Bone scintigraphy using Tc-99m methylene diphosphonate may demonstrate focal increased tracer uptake on the dorsal aspect of the wrist. In any case, it is not utilized much in clinical settings due to its destitute spatial determination.

Surgery ought not to be routinely performed for this condition for esthetic purposes.<sup>[11]</sup> At first, it was too thought that there is an increased chance of recurrence of the entity after surgery. Hence, the entity was managed by symptomatic support.<sup>[3]</sup> Current management protocol includes initial management with a course of NSAIDs. If the patient does not improve, a cast is put from his second to fifth metacarpophalangeal joint. If still the symptoms persist,

surgical management could be opted in which resection of the accessory ossicle is performed.

## CONCLUSION

A case report of a typical case of carpal bossing has been described with a brief review of the literature. The condition needs to be identified early as it may lead to long-term morbidity for the patient.

## Declaration of patient consent

The authors certify that they have obtained all appropriate patient consent.

## Financial support and sponsorship

Nil.

## Conflicts of interest

There are no conflicts of interest.

## REFERENCES

1. Lamphier TA. Carpal bossing. *Arch Surg* 1960;81:1013-5.
2. Grumbach A. *Das Handskelett im Lichte den Röntgenstrahlen*.

Vienna: Braumüller; 1921.

3. Fiolle J. Le “carpe bossu”. *Bull Mem Soc Natl Chir* 1931;57:1687-90.
4. Nguyen V, Choi J, Davis KW. Imaging of wrist masses. *Curr Probl Diagn Radiol* 2004;33:147-60.
5. Foucher G, Binhamer P, Cange S, Lenoble E. Long-term results of splintage for mallet finger. *Int Orthop*. 1996;20:129-31.
6. Kissel P. Conservative management of symptomatic carpal bossing in an elite hockey player: A case report. *J Can Chiropr Assoc* 2009;53:282-9.
7. Bassoe E, Bassoe HH. The styloid bone and carpe bossu disease. *Am J Roentgenol Radium Ther Nucl Med* 1955;74:886-8.
8. Park MJ, Namdari S, Weiss AP. The carpal boss: Review of diagnosis and treatment. *J Hand Surg Am* 2008;33:446-9.
9. Mespreuve M, Vanhoenacker F, Verstraete K. Lunotriquetral coalition, a normal variant that may rarely cause ulnar sided wrist pain. *JBR BTR* 2015;98:72-8.
10. Mespreuve M, De Smet L, De Cuyper K, Waked K, Vanhoenacker F. MRI diagnosis of carpal boss and comparison with radiography. *Acta Radiol* 2017;58:1245-51.

**How to cite this article:** Narayan SH, Raj N, Grewal D, Sahu S. Its not good to be too bossy - Carpal bossing: A case report with review of literature. *Indian J Musculoskelet Radiol* 2022;4:111-4.