

## Case Report

# Atypical case of wrist pain in young with Madelung deformity

Vineet Kumar Vemuri<sup>1</sup>, Gutti Raghu Madhu Mallik<sup>1</sup>, Bhamidipaty Kanaka Durgaprasad<sup>1</sup>, Naga Varaprasad Vemuri<sup>2</sup>

<sup>1</sup>Department of Radiodiagnosis, GITAM Institute of Medical Sciences and Research, Visakhapatnam, <sup>2</sup>Department of Radiology, Swarna Scans and Diagnostics, Vijayawada, Andhra Pradesh, India.



### \*Corresponding author:

Vineet Kumar Vemuri,  
Department of Radiodiagnosis,  
GITAM Institute of  
Medical Sciences and  
Research, Visakhapatnam,  
Andhra Pradesh, India.

[vineetradiology97@gmail.com](mailto:vineetradiology97@gmail.com)

Received: 25 September 2024  
Accepted: 29 October 2024  
Epub Ahead of Print: 02 December 2024  
Published: 21 December 2024

DOI  
10.25259/IJMSR\_50\_2024

### Quick Response Code:



## ABSTRACT

The Vickers ligament is a distinct ligamentous structure that connects the lunate bone and the triangular fibrocartilage complex to the distal radius. It is commonly present in individuals with Madelung deformity, a congenital malformation of the wrist. This ligament restricts the normal growth and movement of the radius, contributing to the characteristic wrist deformity and often leading to pain and functional limitations. Madelung deformity is frequently observed in young females and often presents with symptoms of wrist pain, restricted range of motion, and visible deformity. Here, we describe an intriguing case of a young female patient who presented with wrist pain and was found to have Madelung deformity in her left wrist. This case highlights the importance of recognizing Vickers ligament as a contributing factor to the patient's symptoms and the deformity's progression.

**Keywords:** Vickers ligament, Madelung deformity, Magnetic resonance imaging

## INTRODUCTION

Madelung deformity is a congenital wrist condition, frequently linked to mutations in the SHOX gene, and can often manifest bilaterally.<sup>[1]</sup> A key feature of this deformity is the presence of the Vickers ligament, also known as the radiolunate ligament, which is a short, thick ligament originating from the volar aspect of the distal radius and inserting into the lunate bone, commonly found in individuals with Madelung deformity.<sup>[2]</sup> In addition, the anomalous volar radiotriquetral ligament is another ligament associated with this condition.<sup>[3]</sup>

The Vickers ligament extends across the ulnar aspect of the distal radius, contributing to the distinctive volar and ulnar angulation observed in Madelung deformity. These ligaments play a central role in the pathophysiology of the deformity by creating a tethering effect that restricts growth and alters normal wrist development, exacerbating the abnormal growth patterns of the distal radius. The main clinical concerns for individuals with Madelung deformity include wrist pain, functional impairment, and visible deformity.<sup>[1-3]</sup>

Here, we describe an intriguing case of a young female patient who presented with wrist pain and was found to have Madelung deformity in her left wrist. This case highlights the importance of recognizing Vickers ligament as a contributing factor to the patient's symptoms and the deformity's progression.

## CASE REPORT

A 12-year-old female presented with left wrist pain, with no reported history of trauma. Frontal and lateral radiographs of the left wrist revealed mild dorsal bowing and pronounced radial bowing

This is an open-access article distributed under the terms of the Creative Commons Attribution-Non Commercial-Share Alike 4.0 License, which allows others to remix, transform, and build upon the work non-commercially, as long as the author is credited and the new creations are licensed under the identical terms.

©2024 Published by Scientific Scholar on behalf of Indian Journal of Musculoskeletal Radiology

of the distal radius, accompanied by dorsal subluxation of the ulnar head and a positive ulnar variance [Figures 1a and 1b]. The radiographs also showed a medial and downward inclination of the distal radial metaphysis, with shortening and hypoplasia of the radial physis on the ulnar side. In addition, there was an increased lunate fossa angle, wedging of the proximal carpal row, and proximal migration of the lunate with evidence of lunate subsidence [Figure 1a].

An magnetic resonance imaging (MRI) of the left wrist was performed using T1-weighted images in axial and coronal planes; T2-weighted imaging in coronal, axial, and sagittal planes; proton density fat-saturated images in coronal and sagittal planes; and short tau inversion recovery in coronal sections. A minimal amount of free fluid was observed in the left distal radioulnar joint space. In addition, a thick, band-like ligament was identified at the volar aspect of the distal radius, originating from the metaphysis proximal to the radial epiphysis and inserting on the ulnar margin of both the lunate and triquetral bones, representing the radiolunate and radiotriquetral ligaments [Figure 2a-d].

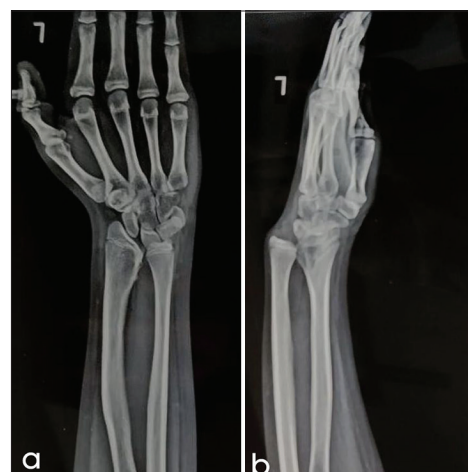Further findings included T2/PD hyperintensities in the ulnar head, suggestive of bone marrow edema, as well as hyperintensity around the extensor carpi ulnaris tendon, consistent with tendinosis. Thinning of the radial epiphysis on the ulnar side and mild proximal migration of the lunate were also noted.

## DISCUSSION

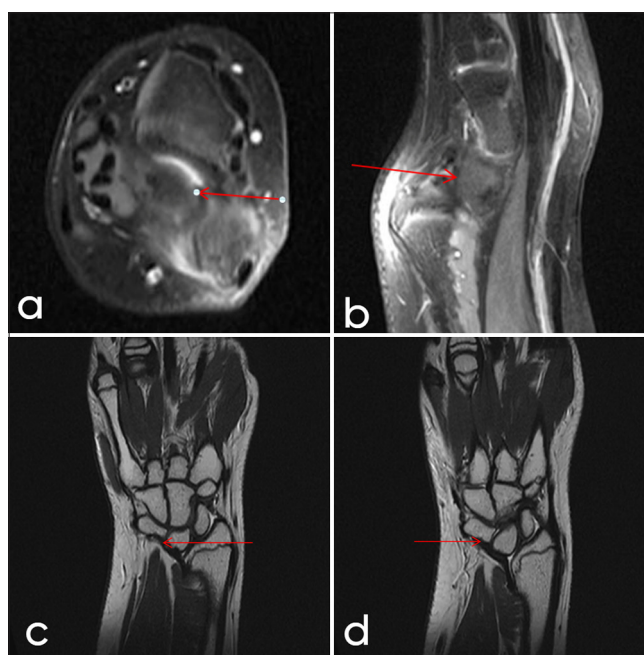
The Vickers ligament is an anomalous structure frequently associated with Madelung deformity, a congenital wrist disorder marked by abnormal growth and curvature of the radius, often causing wrist pain and limited range of motion. Named after Dr. Vickers, who initially described it, this ligament arises from the volar aspect of the distal radius and attaches to the lunate bone, restricting the normal growth and mobility of the wrist.<sup>[1-3]</sup>

In Madelung deformity, the Vickers ligament (or radiolunate ligament) connects the lunate bone and the triangular fibrocartilage complex to the distal radius and is present in the majority of affected patients. The condition commonly affects children aged 8–14, with a higher prevalence in females (female-to-male ratio of 4:1). Madelung deformity is also associated with several genetic and syndromic conditions, such as Turner syndrome, nail-patella syndrome, gonadal dysgenesis, and diaphyseal aclasis.<sup>[4]</sup>

A radial notch at the attachment site of the Vickers ligament and the presence of this anomalous radiolunate ligament can help differentiate Madelung-type deformities from true congenital Madelung deformities.<sup>[5]</sup> Various conditions can produce a Madelung-like or pseudo-Madelung deformity; however, they lack the characteristic Vickers ligament or the anomalous radiotriquetral ligaments seen in true Madelung deformity [Table 1]. MRI is the preferred imaging modality



**Figure 1:** (a) Frontal and (b) lateral radiographs of the left hand demonstrate Madelung deformity with positive ulnar variance. There is lunate subsidence and wedge-shaped proximal carpal row. Dorsal subluxation of the ulnar head is causing “bayonet” like deformity.



**Figure 2:** A 12-year-old female. (a) Axial T2, (b) sagittal, (c) coronal fluid sensitive magnetic resonance sequences showing radiolunate (Vickers ligament) (red arrow) with associated madelung deformity. (d) Coronal T2W image showing radiotriquetral ligament (red arrow).

for visualizing the Vickers ligament and related abnormalities associated with Madelung deformity. This imaging allows for optimal assessment of the commonly associated radiolunate ligament and, less frequently, the radiotriquetral ligament.

**Table 1:** Conditions causing Madelung-like or pseudo-Madelung deformity that does not feature abnormal Vickers ligament or radio-triquetral ligaments.

S. No.	Differential diagnosis	Differentiating features
1.	Pseudo-Madelung Deformity	Characterized by negative ulnar variance, resulting in radial deviation
2.	Multiple Epiphyseal Dysplasia and Ollier Disease	Morphologically similar to classic Madelung deformity, but lacks the presence of the Vickers ligament or anomalous radiotriquetral ligament
3.	Turner's syndrome	May show decreased carpal angles resembling Madelung deformity but is also associated with a shortened 4 <sup>th</sup> metacarpal and osteopenia
4.	Infection or Chronic Arthritis	Infection or inflammation can lead to premature closure of the epiphysis, resulting in a pseudo-Madelung-like deformity

In addition, MRI can identify other pathologies such as tendinitis and joint effusions. In some cases, radiolunate dislocation due to the Vickers ligament may be visible on both forearm radiographs and MRI.<sup>[3]</sup>

Madelung deformity may present as an isolated condition or with symptoms such as discomfort, wrist pain, reduced grip strength, and limited wrist mobility.<sup>[6]</sup> For individuals with mild symptoms, conservative treatment with non-steroidal anti-inflammatory drugs (NSAIDs) and activity modification may be effective.<sup>[7]</sup> In young patients with progressive deformity, surgical resection of the Vickers ligament and any anomalous radiotriquetral ligament can alleviate symptoms and help prevent further progression. For those who have reached skeletal maturity and experience persistent pain or restricted wrist mobility, surgical intervention may be considered to improve function.<sup>[8,9]</sup>

## CONCLUSION

Madelung deformity is a rare congenital condition often associated with the anomalous Vickers ligament, which restricts normal wrist development and contributes to pain, deformity, and limited wrist function. This case emphasizes the role of MRI in identifying the Vickers ligament and associated anomalies, which are pivotal in distinguishing true Madelung deformity from similar conditions and pseudo-Madelung deformities. In managing symptomatic cases, conservative approaches such as NSAIDs and activity modifications are effective for mild symptoms, while surgical intervention may be required in progressive or severe cases to improve wrist function and alleviate pain. Early recognition and appropriate treatment of Madelung deformity are crucial in mitigating long-term morbidity and functional impairment.

## Ethical approval

Institutional Review Board approval is not required.

## Declaration of patient consent

The authors certify that they have obtained all appropriate patient consent.

## Financial support and sponsorship

Nil.

## Conflicts of interest

There are no conflicts of interest.

## Use of artificial intelligence (AI)-assisted technology for manuscript preparation

The authors confirm that there was no use of artificial intelligence (AI)-assisted technology for assisting in the writing or editing of the manuscript, and no images were manipulated using AI.

## REFERENCES

- Huguet S, Leheup B, Aslan M, Muller F, Dautel G, Journeau P, et al. Radiological and clinical analysis of Madelung's deformity in children. *Orthop Traumatol Surg Res* 2014;100:S349-52.
- Vickers D, Nielsen G. Madelung deformity: Surgical prophylaxis (physiylaxis) during the late growth period by resection of the dyschondrosteosis lesion. *J Hand Surg Br* 1992;17:401-7.
- Hanson TJ, Murthy NS, Shin AY, Kakar S, Collins MS. MRI appearance of the anomalous volar radiotriquetral ligament in true Madelung deformity. *Skeletal Radiol* 2019;48:915-8.
- Ghatan AC, Hanel DP. Madelung deformity. *J Am Acad Orthop Surg* 2013;21:372-82.
- Flores DV, Umpire DF, Rakhra KS, Jibri Z, Belmar GA. Distal radioulnar joint: Normal anatomy, imaging of common disorders, and injury classification. *Radiographics* 2023;43:e220109.
- Ali S, Kaplan S, Kaufman T, Fenerty S, Kozin S, Zlotolow DA. Madelung deformity and Madelung-type deformities: A review of the clinical and radiological characteristics. *Pediatr Radiol* 2015;45:1856-63.
- Shahi P, Sudan A, Sehgal A, Meher D, Meena U. Madelung deformity of the wrist managed conservatively. *Cureus* 2020;12:e8225.
- Harley BJ, Brown C, Cummings K, Carter PR, Ezaki M. Volar ligament release and distal radius dome osteotomy for correction of Madelung's deformity. *J Hand Surg Am* 2006;31:1499-506.
- Farr S, Zlotolow DA, Bachy M, Peymani A, Hülsemann W, Winge MI. State of the art review: The pathogenesis and management of Madelung deformity. *J Hand Surg Eur Vol* 2023;48:1116-25.

**How to cite this article:** Vemuri VK, Madhu Mallik GR, Durgaprasad BK, Vemuri NV. Atypical case of wrist pain in young with Madelung deformity. *Indian J Musculoskelet Radiol*. 2024;6:125-7. doi: 10.25259/IJMSR\_50\_2024



# Advanced Certification and MSS India Hybrid Fellowship in MSK Imaging



Starting on 19<sup>th</sup> April, 2026



9 Months Hybrid Fellowship

## Fellowship Highlights



26 Weeks of structured online learning with expert faculty



Convenient Weekend Classes – Sundays, 4–8 PM



Comprehensive MSK Curriculum covering sports injuries, arthritis, trauma, tumors, spine & interventions



Case-Based Learning with image interpretation and interactive discussions



Onsite Hands-on Training in MSK Ultrasound



Exit Exam + Fellowship Certification in Musculoskeletal Radiology



Convocation at MSS India Annual Conference



Optional Exit exam and Cadaveric Intervention Workshop



*"Where expertise meets excellence, Elevate your career through MSS India Advanced Certification & Hybrid Fellowship in MSK Imaging".*

**Dr. M. V. Chalapathi Rao**  
President, MSS India



*"Refinement & Recognition in radiological excellence. Reshape your expertise through expert mentorship, cutting-edge insights, and a truly transformative learning experience through MSS India Advanced Certification & Hybrid Fellowship in MSK Imaging."*

**Dr. Nishith Kumar**  
Secretary General, MSS India

## International Faculty

Dr. Christine B. Chung  
USA

Prof. James Griffith  
Hong Kong

Prof. Hema N. Choudur  
Canada

Dr. Mark A. Davies  
UK

Dr. Manickam "Nicks" Kumaravel  
USA

Dr. Steven James  
UK

Prof. Winston Rennie  
UK

Prof. Rajesh Botchu  
UK

Dr. Avneesh Chhabra  
USA

Dr. Girish Gandikota  
USA

Dr. Sameer Raniga  
Oman

Dr. Steven Wong  
Singapore

Dr. Raj Negi  
UK

Dr. Raj Chari  
UK

Dr. Ankit A. Tandon  
Singapore

Dr. Jyoti Panwar  
Australia

Dr. Muthukumar T.  
UK

Dr. Iqbal S. Ganie  
South Africa

Dr. Amit Katyan  
Canada

Dr. Muthukumar Chandramohan  
UK

Dr. Samir Paruthikunnan  
UK

and many more...

## National Faculty

Dr. Abhimanyu Kelkar  
Pune

Dr. Jayaraj Govindaraj  
Chennai

Dr. Vemuri Varaprasad  
Vijayawada

Dr. N. Chidambaranathan  
Chennai

Dr. Sandeep Velicheti  
Vijayawada

Dr. Malini Lawande  
Mumbai

Dr. Hiral R. Choudhury  
Kolkata

Dr. Joshita Singh  
Pune

Dr. Ankur J. Shah  
Ahmedabad

Dr. Joban Babhulkar  
Pune

Dr. Darshana Sanghvi  
Mumbai

Prof. Samarendra Narayan  
Lucknow

Prof. Dharmendra K. Singh  
New Delhi

Dr. Vardhan Joshi  
Pune

Prof. Ankur Goyal  
New Delhi

Dr. Pushpa BT  
Coimbatore

Dr. Ramakrishna N.  
Hyderabad

Dr. Srijita Ghosh  
Kolkata

Dr. Khushboo Pilonia  
Noida

Dr. Amit Sahu  
New Delhi

Dr. Satish Babu M.  
Vijayawada

Dr. Anupama Patil  
Pune

Dr. Neha Nischal  
New Delhi

Dr. Gaurav K. Sharma  
Jaipur

Dr. Vaishali Upadhyaya  
Lucknow

Dr. Madhavi K.  
Vellore

Dr. Sonal Saran  
Uttarakhand

Dr. Stanzin Spalkit  
New Delhi

Dr. Rajat Jain  
New Delhi

Dr. Suvinay Saxena  
Bhopal

Dr. Surendra K. Bugata  
Vizag

Dr. Chinmay Mehta  
Mumbai

Dr. Ankita Ahuja  
Mumbai

Dr. Sagar Tomar  
Noida

Dr. Neeti Gupta  
Delhi

and many more... Register on <https://www.mssmskfellowship.com/>

**REGISTER NOW**

