

Original Article

## Extra-articular findings in patients with suspected labral tear and value of screening pelvis sequence

Patrick Hurley<sup>1</sup>, Jawad Ahmad<sup>1</sup>, Rajesh Botchu<sup>2</sup>, Steven James<sup>2</sup>

<sup>1</sup>Department of Medicine, University of Birmingham, College of Medical and Dental Sciences, <sup>2</sup>Department of Musculoskeletal Radiology, Royal Orthopedic Hospital, Birmingham, England.



**\*Corresponding author:**

Rajesh Botchu,  
Department of Musculoskeletal  
Radiology, Royal Orthopedic  
Hospital, Birmingham,  
England.

drbrajesh@yahoo.com

Received: 28 October 2021  
Accepted: 19 September 2022  
Epub Ahead of Print: 13 October 2022  
Published: 21 December 2022

DOI  
10.25259/IJMSR\_52\_2021

Quick Response Code:



### ABSTRACT

**Objectives:** There are multiple etiologies of hip pain, of which labral tear is one of the most common in young adults which may be difficult to distinguish on history and clinical examination. Labral tears can be diagnosed using high-resolution non-contrast magnetic resonance imaging (MRI) or MR arthrogram that involves imaging the concerned hip. At our institute, we perform an additional proton density fat saturated axial sequence of the pelvis to screen for alternative pathology and we investigate the value of this in this study.

**Material and Methods:** A retrospective review of high-resolution non-arthrographic 3T MR of hips that were referred from young adult hip services with a history of hip or groin pain and the clinical suspicion of a labral tear over 2 years was performed. Those <50 years were included in the study.

**Results:** Of 648 patients with suspected labral tears, 18% showed evidence of extra-articular hip pathologies (sacroiliac joint pathology, iliopsoas pathology, and ischiofemoral impingement) on MRI. This study has shown that approximately one in five patients with a clinically suspected labral tear showed radiological evidence of extra-articular hip pathology (sacroiliac joint pathology, iliopsoas pathology, ischiofemoral impingement, and hamstring pathology). There is therefore the potential for misdiagnosis and increased morbidity if these alternative diagnoses were not appreciated.

**Conclusion:** A high-resolution hip MRI protocol for suspected labral tears of the hip joint should include at least one sequence of the entire pelvis to evaluate for extra-articular findings.

**Keywords:** labral tear, sacroiliac joint pathology, iliopsoas pathology, ischiofemoral impingement, pelvic MRI

### INTRODUCTION

The 2017 Royal College of Surgeons commission into pain arising from the hip in adults reported that each year approximately 450 patients per 100,000 will present to primary care with hip pain.<sup>[1]</sup> Hip pain has been shown to significantly reduce the quality of life<sup>[2]</sup> and fitness levels in adults<sup>[3]</sup> following disease severity. One of the most common causes of hip pain in young adults is labral tears.<sup>[4]</sup> Labral tears may present with either anterior hip pain or occasionally groin pain<sup>[5]</sup> and can have various etiologies.<sup>[6]</sup> These may include anatomical abnormalities such as femoroacetabular impingement, capsular laxity, and dysplasia of the hip as well as trauma.<sup>[6]</sup> The labrum has many important roles in the function of the hip such as shock absorption, lubrication, pressure distribution, and stability support.<sup>[7,8]</sup>

It has however been reported that patient perception of hip pain may arise due to pathology of anatomically close structures such as the pelvis<sup>[9]</sup> due to the phenomenon of referred pain.<sup>[10]</sup>

This is an open-access article distributed under the terms of the Creative Commons Attribution-Non Commercial-Share Alike 4.0 License, which allows others to remix, transform, and build upon the work non-commercially, as long as the author is credited and the new creations are licensed under the identical terms.

©2022 Published by Scientific Scholar on behalf of Indian Journal of Musculoskeletal Radiology

The pelvis consists of the ilium, ischium, pubis, sacrum, and coccyx. The pelvis and the hip joint share sensory nerve roots; therefore, it is common for pelvic related pathologies to have symptoms that mimic those of the hip joint.<sup>[9]</sup> Despite its prevalence, the pathophysiology of pain in the musculoskeletal system is still not fully understood,<sup>[11]</sup> with referred pain proving especially challenging to develop a unifying theory for.<sup>[12]</sup>

Imaging investigations in suspected labral tears include the use of radiographs, MR arthrogram, and high resolution non-contrast magnetic resonance imaging (MRI).<sup>[4]</sup> The findings from these investigations are then used to guide management into either a conservative or surgical path. Commonly, in patients presenting with hip pain, a radiograph is obtained either in primary or secondary care. If deemed appropriate, patients may then be offered an MRI scan of the hip to further assess for pathology which may not be evident on radiographs.<sup>[13]</sup> The crucial aspect of these images, regardless of imaging modality, is to obtain information relating to local disease processes that may be missed through radiographs of the hip alone. As outlined above, hip pain may be due to a myriad of causes relating to both bone and soft-tissue pathology,<sup>[14-16]</sup> and as such imaging of the pelvis may prove effective in identifying potential causes of pain.

This study investigated the importance of performing a screening pelvic MRI in patients with hip pain due to suspected labral tear and evaluates the extra-articular findings. The null hypothesis for this study was that no additional information relating to the etiology of patient pain could be garnered from MRI imaging of the pelvis.

## MATERIAL AND METHODS

A retrospective review of high resolution non-arthrographic 3T MR of the hips that were referred from young adult hip services with a history of hip or groin pain and the clinical suspicion of a labral tear over 2 years was performed. All patients had intermediate weighted sequences with and without fat suppression in coronal oblique, sagittal oblique, and axial oblique planes. (Matrix- 512 × 358, FOV- 16–18 cm, 3 mm slice thickness, 0.3 mm interslice gap, TR 3000–4000, TE- 30–40). Those <40 years were included in the study.

## RESULTS

The average age of the cohort was 32 years (range 15–50 years) with a female predominance (M: F, 2:1). As shown in [Table 1], pelvic MRI scans for 648 patients presenting with suspected labral tears were reviewed by a consultant radiologist. Of these, 480 (74%) showed no pelvic pathology, and 114 (18%) had evidence of pelvic pathology. Forty-five (8%) showed other causes of pathology (hamstring and unspecified). [Figures 1-3] Pathologies of the iliopsoas,

ischiofemoral interval, and trochanteric bursa can be assessed on sequences of labral tears but sacroiliac abnormalities can only be seen on screening pelvis sequence.

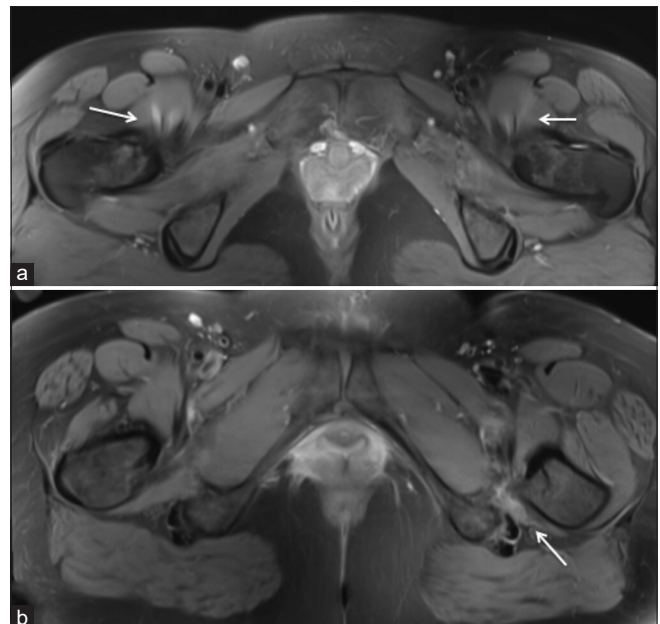
## DISCUSSION

This study shows that in patients presenting with suspected labral tears, 18% (114 in 648) demonstrated pelvic pathology, which may play a role in pain etiology. For this study, sacroiliac joint pathology, iliopsoas pathology, and ischiofemoral impingement most frequently present on pelvic MRIs present with hip pain. The sacroiliac joints connect the hip bones posterolaterally and function primarily to bear the weight of the axial skeleton and transfer this to the hips.<sup>[17]</sup> The sacroiliac joint is supported by the anterior and posterior sacroiliac ligament, interosseous ligament, sacrotuberous ligament, sacrospinous ligament, and iliolumbar ligament. In age-related degeneration, these ligaments may become unable

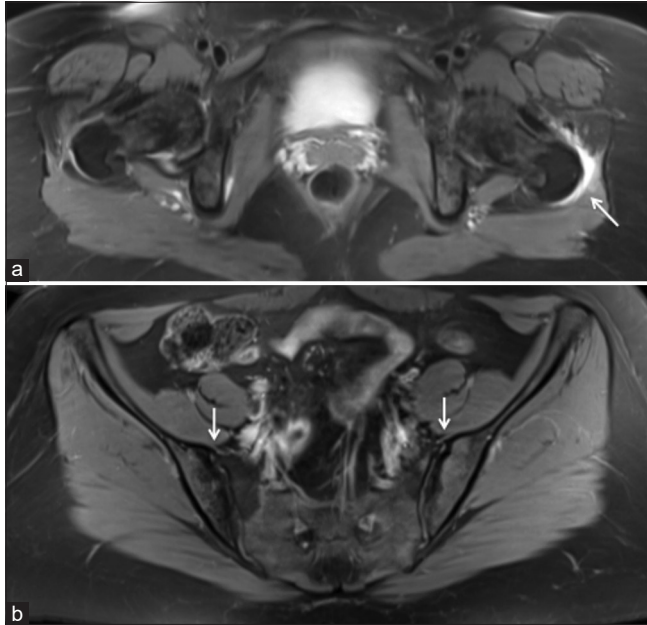**Table 1:** Number of additional pathologies identified on screening PDFS axial of pelvis.

|                              | Number of patients |
|------------------------------|--------------------|
| No extra-articular pathology | 480                |
| Sacroiliac joint pathology   | 42                 |
| Iliopsoas pathology          | 39                 |
| Ischiofemoral impingement    | 33                 |
| Hamstrings pathology         | 18                 |
| Others                       | 36                 |

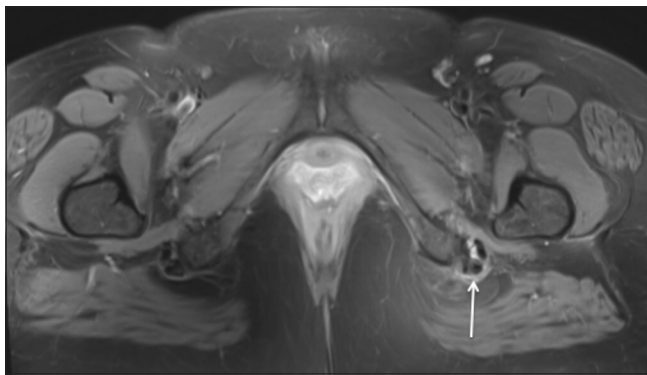PDFS: Proton density fat saturated



**Figure 1:** Proton density fat saturated (PDFS) axial demonstrating edema involving both iliopsoas (arrows) (a) and left ischiofemoral impingement (arrow) (b).



**Figure 2:** PDFS axial demonstrating edema in relation to the left trochanteric bursitis (arrow) (a) and bilateral chronic sacroilitis (arrow) (b).



**Figure 3:** PDFS axial demonstrating edema in relation to the left hamstrings (arrow).

to maintain tension and as such allow for hypermobility within the joint, degeneration of joint spaces may also lead to hypomobility.<sup>[18]</sup> In both instances, this may be experienced as pain. Sacroiliac joint pain may be challenging to diagnose due to its array of presentations in regions surrounding the pelvis.<sup>[18]</sup>

The iliopsoas is a large compound muscle found within the inner hip with the ability to function as a single unit or as separate muscles.<sup>[19]</sup> Comprised of psoas major, psoas minor, and the iliacus muscle, the iliopsoas plays a key role in maintaining posture and in dynamic movements of the hip.<sup>[20]</sup> Pain originating from the iliopsoas has also been reported as being challenging to diagnose, again due to its preponderance to manifest as referred pain.<sup>[21]</sup> Ischiofemoral impingement is defined as a reduction in the space between

the lateral aspect of the os ischium and the lesser trochanter of the femur.<sup>[22]</sup> It is an uncommon and challenging diagnosis responsible for hip pain.<sup>[23]</sup>

Given the challenging nature of these diagnoses in suspected labral tears, it is both appropriate and pertinent that patients should receive pelvic MRIs to investigate for pathologies, which may lead to referred pain. This study shows that approximately one in five patients may benefit from a screening pelvic MRI as opposed to an isolated MRI of the hip joint when presenting with suspected labral tears. This can either be an axial or coronal fluid sensitive sequence (proton density fat saturated [PDFS] or STIR). The additional time needed for this screening MRI of the pelvis is hence justifiable.

The main limitation of this study is the relatively few numbers of patient scans assessed. This was an imaging study and no clinical correlation of these findings was done.

## CONCLUSION

In the assessment of patients presenting with suspected labral tears, clinicians should be aware of the potential of referred pain from local pelvic structures. To exclude common pelvic pathologies, a high-resolution hip MRI protocol should include a screening MRI of the pelvis.

## Declaration of patient consent

Institutional Review Board (IRB) permission was obtained for the study.

## Financial support and sponsorship

Nil.

## Conflicts of interest

There are no conflicts of interest.

## REFERENCES

1. Bierma-Zeinstra SM, Lipschart S, Njoo KH, Bernsen R, Verhaar J, Prins A, *et al.* How do general practitioners manage hip problems in adults? *Scand J Prim Health Care* 2000;18:159-64.
2. Dawson J, Linsell L, Zondervan K, Rose P, Randall T, Carr A, *et al.* Epidemiology of hip and knee pain and its impact on overall health status in older adults. *Rheumatology (Oxford)* 2004;43:497-504.
3. Łyp M, Kaczor R, Cabak A, Tederko P, Włostowska E, Stanisławska I, *et al.* A water rehabilitation program in patients with hip osteoarthritis before and after total hip replacement. *Med Sci Monit* 2016;22:2635-42.
4. Su T, Chen GX, Yang L. Diagnosis and treatment of labral tear. *Chin Med J (Engl)* 2019;132:211-9.

5. Burnett RS, Rocca GJ, Prather H, Curry M, Maloney WJ, Clohisey JC. Clinical presentation of patients with tears of the acetabular labrum. *J Bone Joint Surg Am* 2006;88:1448-57.
6. Parmar R, Parvizi J. The multifaceted etiology of acetabular labral tears. *Surg Technol Int* 2010;20:321-7.
7. Groh MM, Herrera J. A comprehensive review of hip labral tears. *Curr Rev Musculoskelet Med* 2009;2:105-17.
8. Hip Labral Tear: Symptoms and Surgery University of Utah Health. <https://healthcare.utah.edu/orthopaedics/specialties/hip-pain/labral-tear.php> [Last accessed on 2020 Oct 25].
9. Torstensson T, Butler S, Lindgren A, Peterson M, Eriksson M, Kristiansson P. Referred pain patterns provoked on intra-pelvic structures among women with and without chronic pelvic pain: A descriptive study. *PLoS One* 2015;10:e0119542.
10. Arendt-Nielsen L, Fernández-de-Las-Peñas C, Graven-Nielsen T. Basic aspects of musculoskeletal pain: From acute to chronic pain. *J Man Manip Ther* 2011;19:186-93.
11. Graven-Nielsen T, Arendt-Nielsen L. Assessment of mechanisms in localized and widespread musculoskeletal pain. *Nat Rev Rheumatol* 2010;6:599-606.
12. Graven-Nielsen T. Fundamentals of muscle pain, referred pain, and deep tissue hyperalgesia. *Scand J Rheumatol Suppl* 2006;122:1-43.
13. Wilson JJ, Furukawa M. Evaluation of the patient with hip pain. *Am Fam Physician* 2014;89:27-34.
14. Battaglia PJ, D'Angelo K, Kettner NW. Posterior, lateral, and anterior hip pain due to musculoskeletal origin: A narrative literature review of history, physical examination, and diagnostic imaging. *J Chiropr Med* 2016;15:281-93.
15. Luthra JS, Al-Habsi S, Al-Ghanami S, Ghosh S, Al-Muzahemi K. Understanding painful hip in young adults: A review article. *Hip Pelvis* 2019;31:129-35.
16. Tyler TF, Nicholas SJ. Rehabilitation of extra-articular sources of hip pain in athletes. *N Am J Sports Phys Ther* 2007;2:207-16.
17. Ortho NC. <https://www.orthonc.com/index.php?p=education-research/spine/patient-education-spine-sacroiliac-joint-syndrome> [Last accessed on 2020 Sep 07].
18. Hansen HC, Li SH. Sacroiliac joint pain and dysfunction. *Pain Physician* 2003;6:179-89.
19. Bordonni B, Varacallo M. Anatomy, Bony Pelvis and Lower Limb, Iliopsoas Muscle. Treasure Island, FL: StatPearls Publishing; 2022.
20. Arbanas J, Klasan GS, Nikolic M, Jerkovic R, Miljanovic I, Malnar D. Fibre type composition of the human psoas major muscle with regard to the level of its origin. *J Anat* 2009;215:636-41.
21. Tufo A, Desai GJ, Cox WJ. Psoas syndrome: A frequently missed diagnosis. *J Am Osteopath Assoc* 2012;112:522-8.
22. Gollwitzer H, Banke JJ, Schauwecker J, Gerdesmeyer L, Suren C. How to address ischiofemoral impingement? Treatment algorithm and review of the literature. *J Hip Preserv Surg* 2017;4:289-98.
23. Wilson MD, Keene JS. Treatment of ischiofemoral impingement: Results of diagnostic injections and arthroscopic resection of the lesser trochanter. *J Hip Preserv Surg* 2016;3:146-53.

**How to cite this article:** Hurley P, Ahmad J, Botchu R, James S. Extra-articular findings in patients with suspected labral tear and value of screening pelvis sequence. *Indian J Musculoskelet Radiol* 2022;4:94-7.